

B O R D E A U X



PERSPECTIVES 2019

November Friday 29



My nightmarish case with coelioscopic surgery

Marc Coggia



Hôpitaux Universitaires
Paris Ile-de-France Ouest

RAYMOND POINCARÉ • BERCK
AMBROISE PARÉ • SAINTE PÉRINE

ASSISTANCE
PUBLIQUE

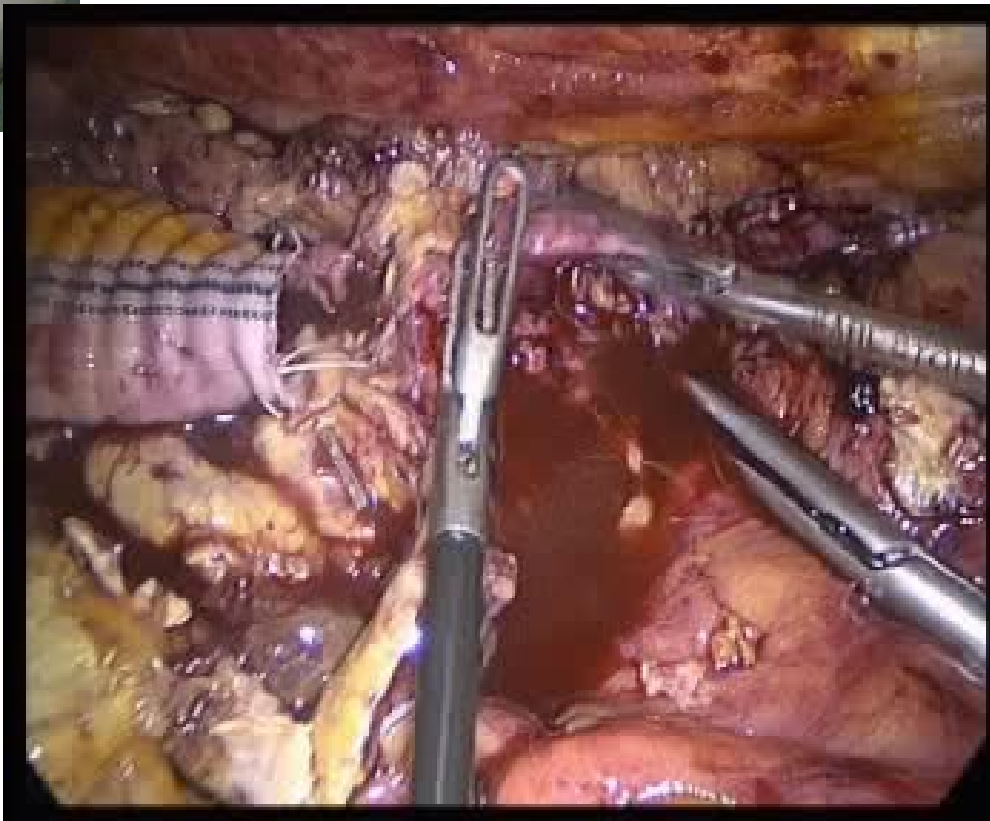
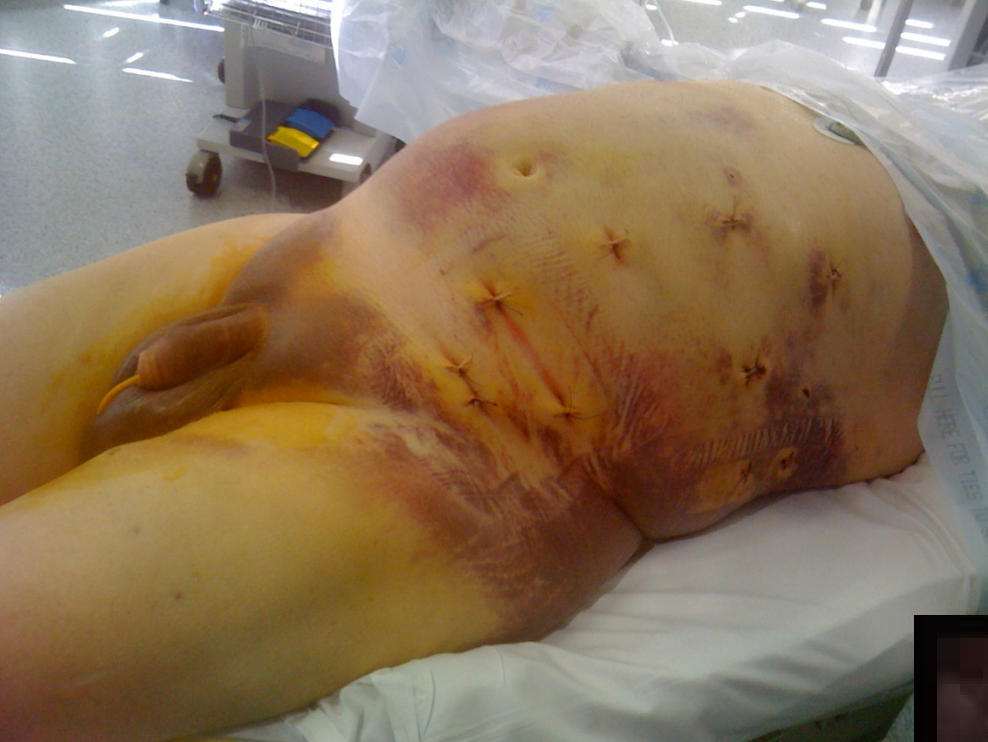

HÔPITAUX
DE PARIS

UNIVERSITÉ DE
VERSAILLES
ST-QUENTIN-EN-YVELINES

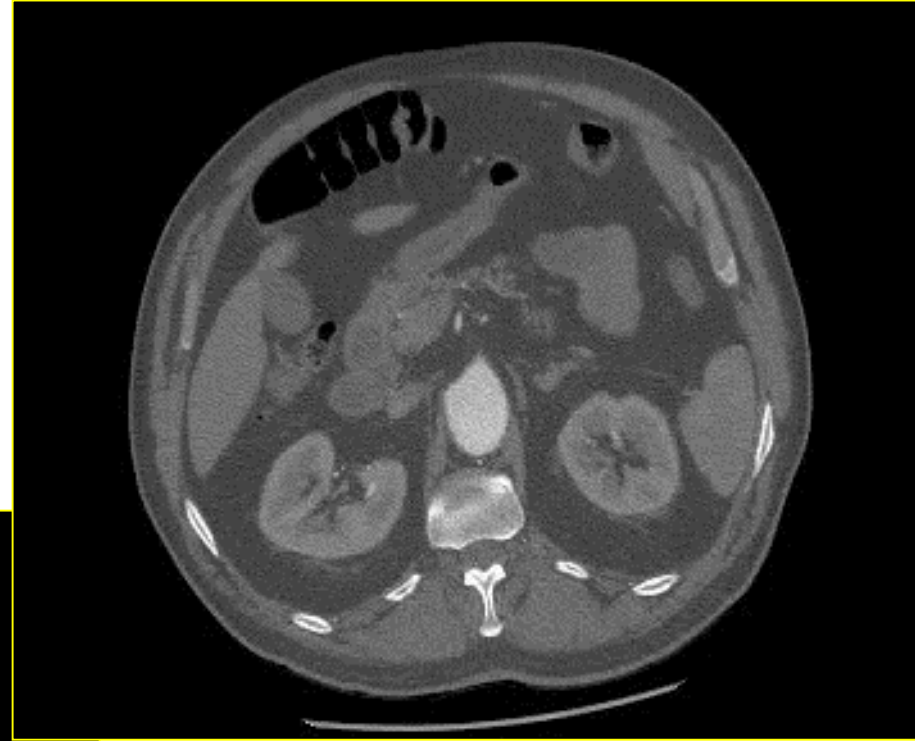
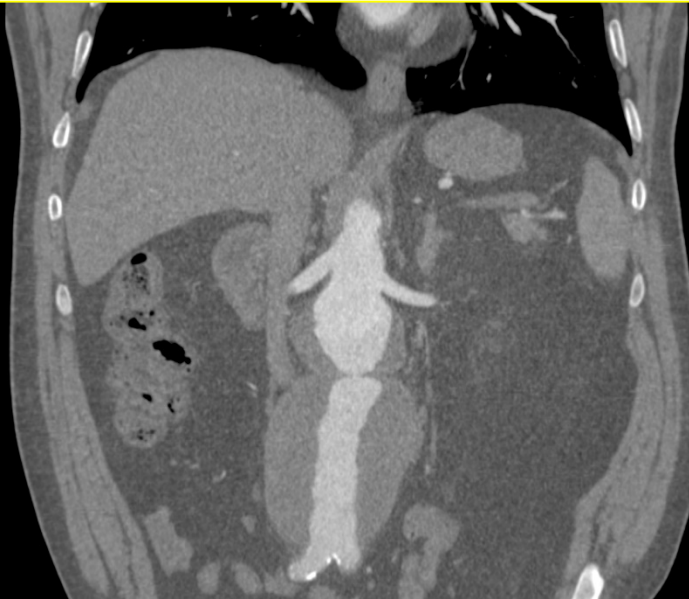

Pas de conflit d'intérêt

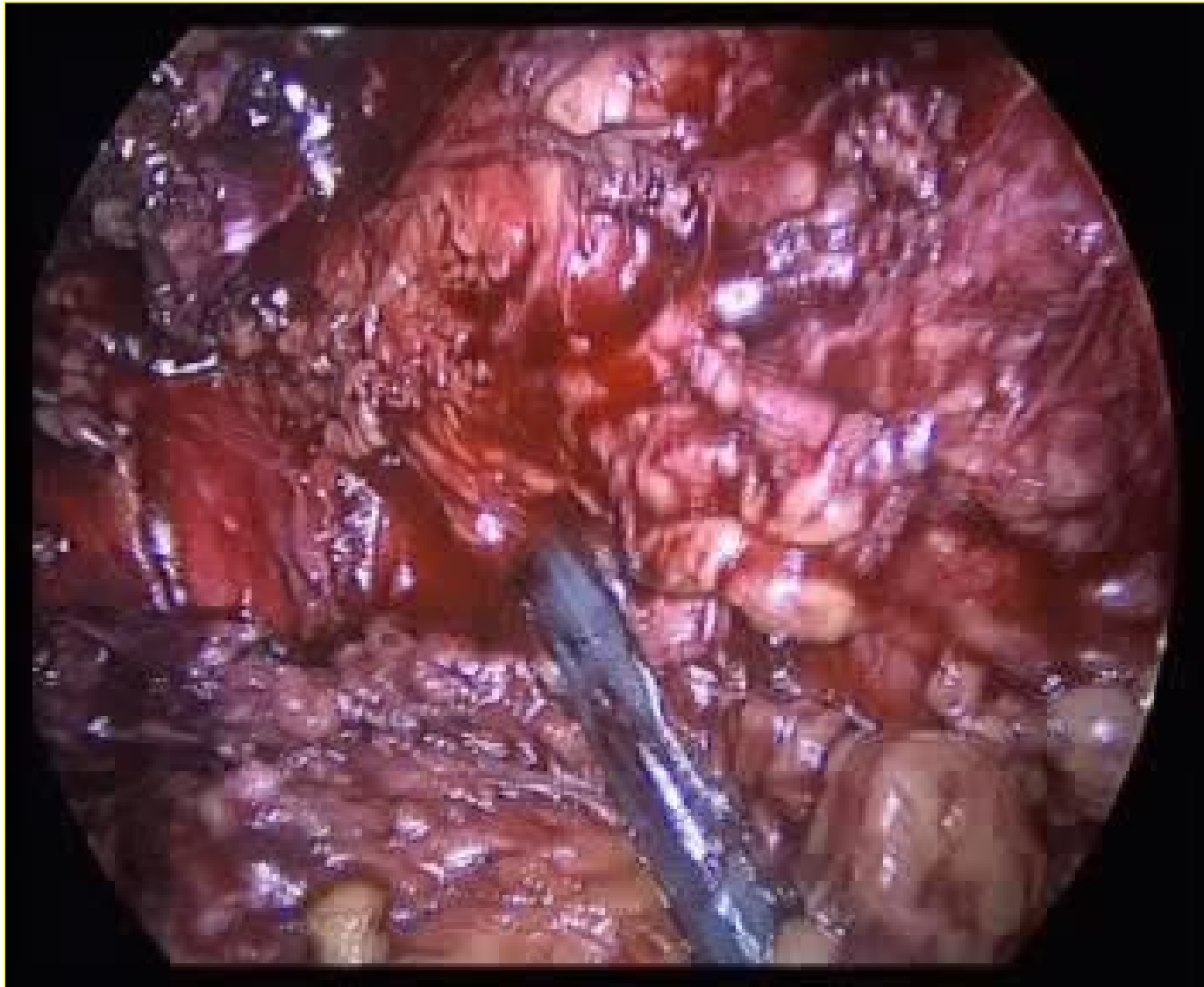


Case

- Man, 58 y
- HTA, diabetes, COPD
- AAA 81mm



Intervention: laparoscopic tube graft

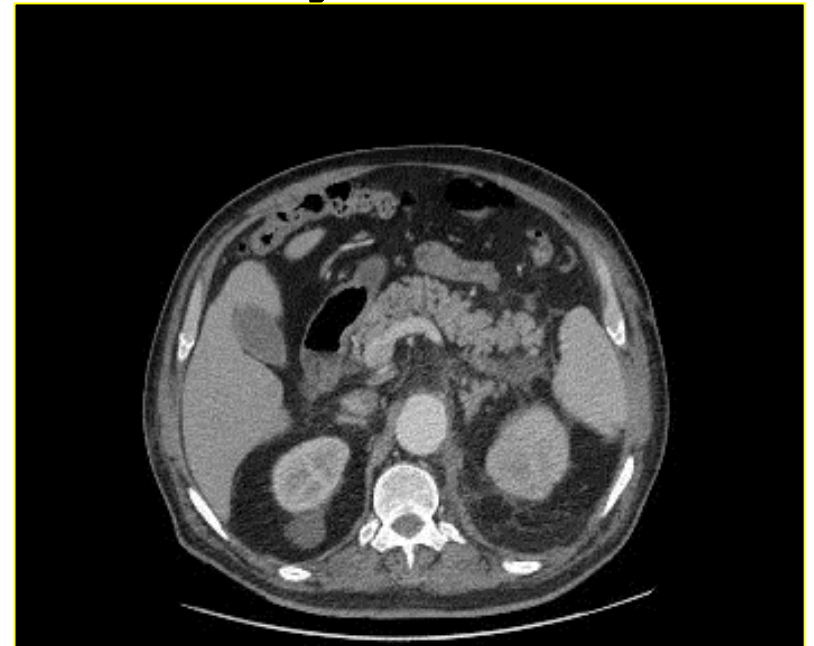


Laparoscopy + conversion: tube graft

Operative time (min)	270
Aortic clamping time (min)	65
Suprarenal clamping time (min)	30
Blood loss (ml)	4500

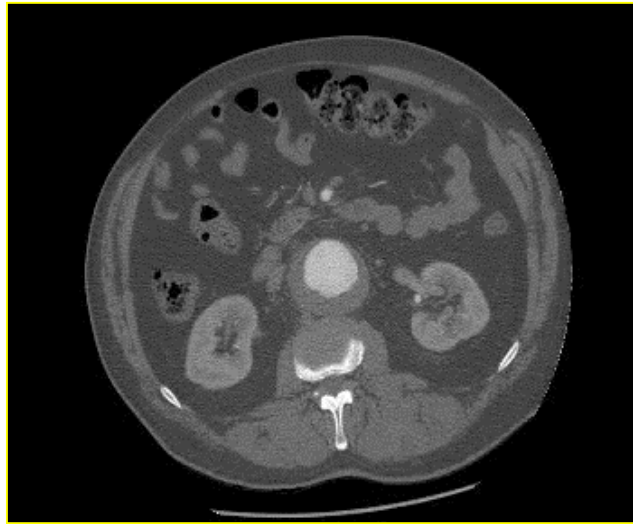
Day 0-Day 36

- Reintervention for bleeding day 0
- Ventilation support day 7
- Renal insufficiency without dialysis
- Pneumopathy
- Graft infection?



Conclusion

- Better planification with preoperative CTscan



- No acrobatics (juxtarenal AAA?)
- Conversion in cases of difficulties +++
- ...Avoid the doctor of the patient in the OT!!