

# UP AND OVER APPROACH TO LOWER LIMB INTERVENTIONS: A WORD OF CAUTION

LORENZO PATRONE

VASCULAR AND INTERVENTIONAL RADIOLOGIST

West London

Vascular and  
Interventional Centre

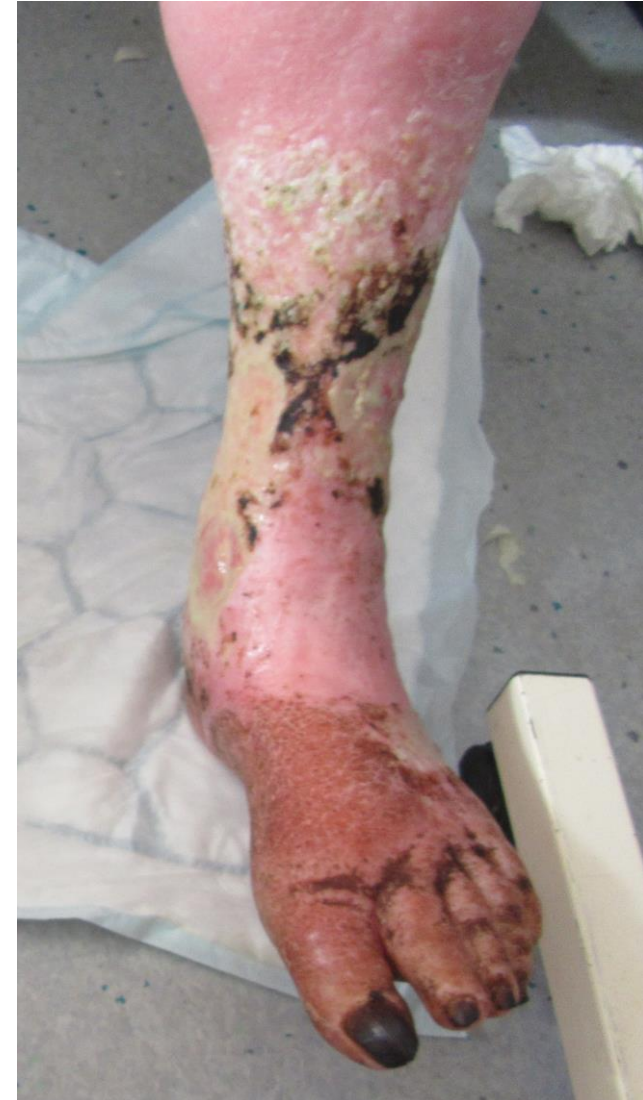

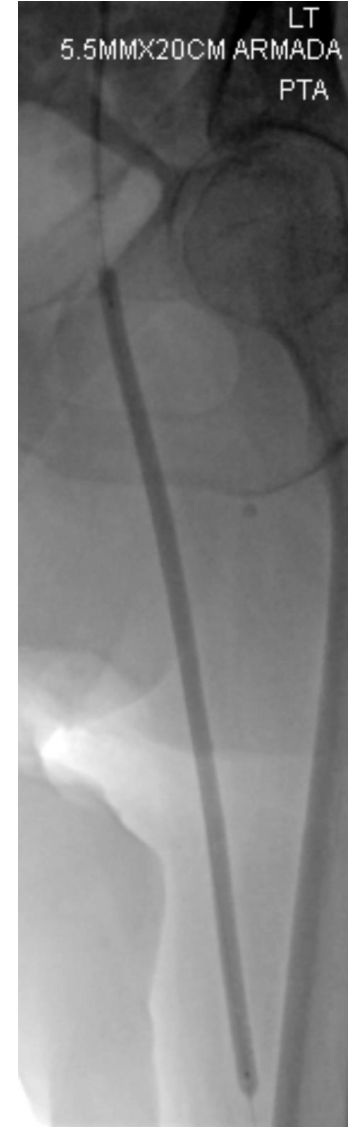
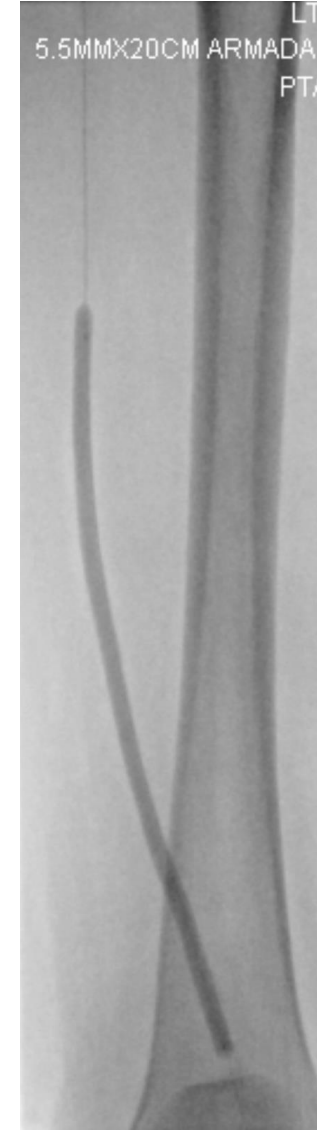

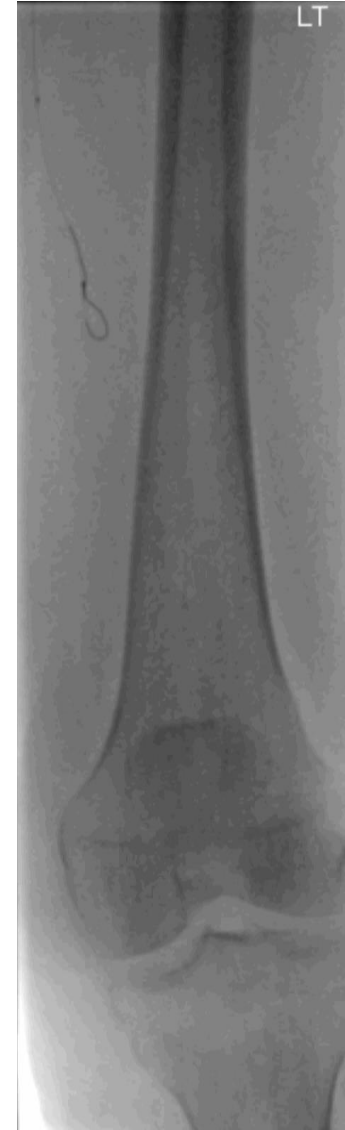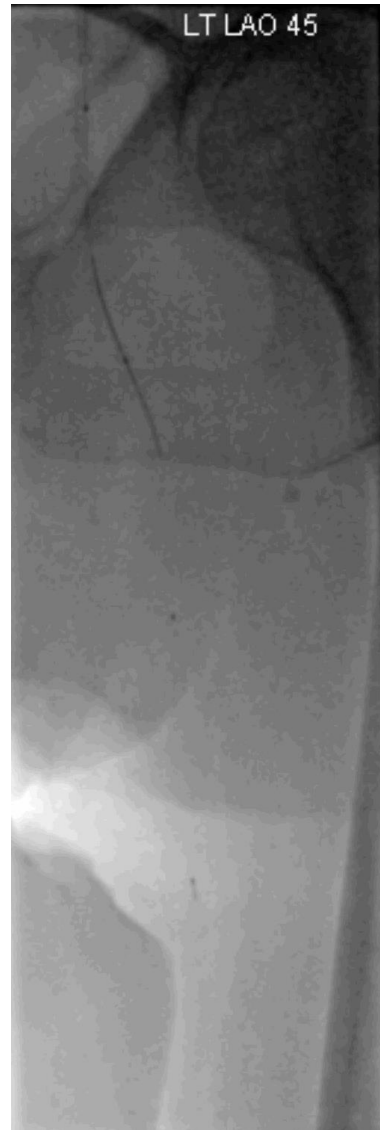



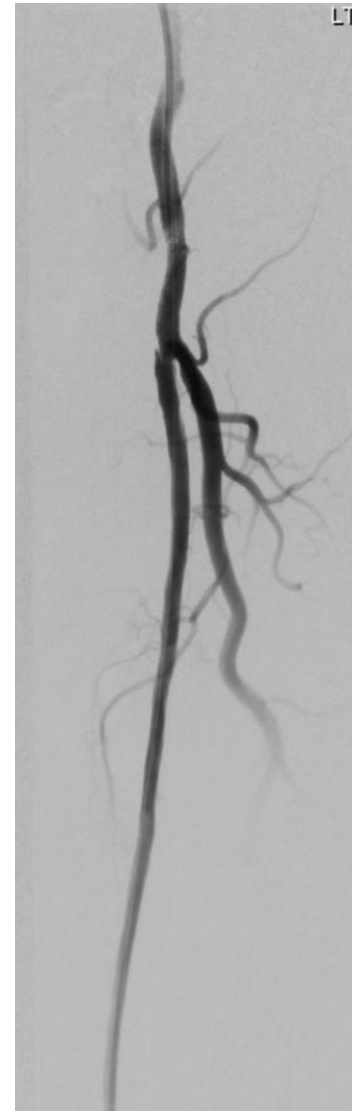
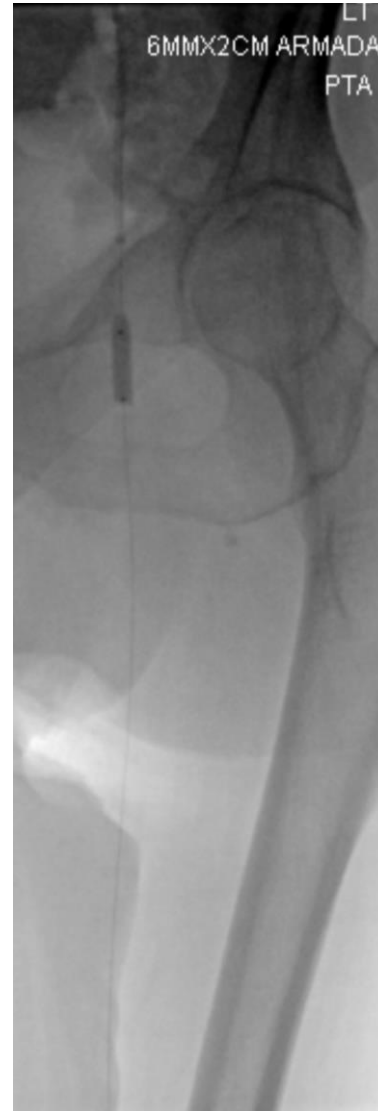Jan 2020


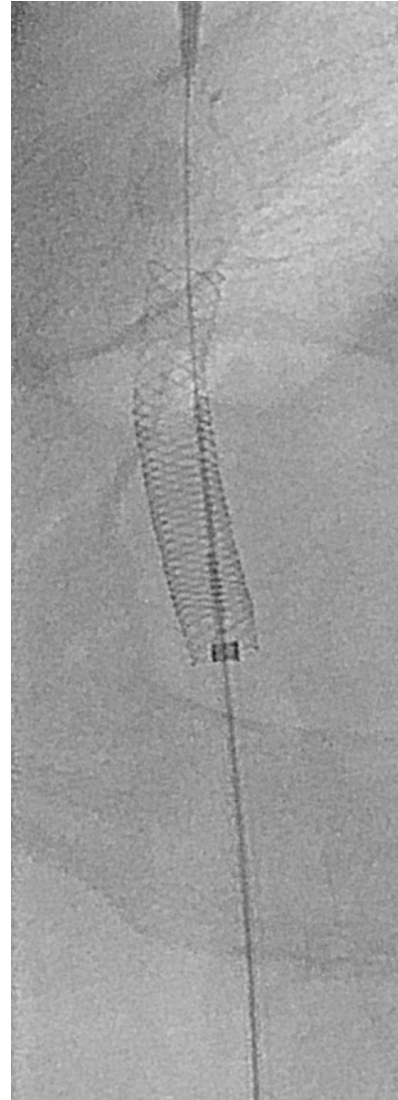
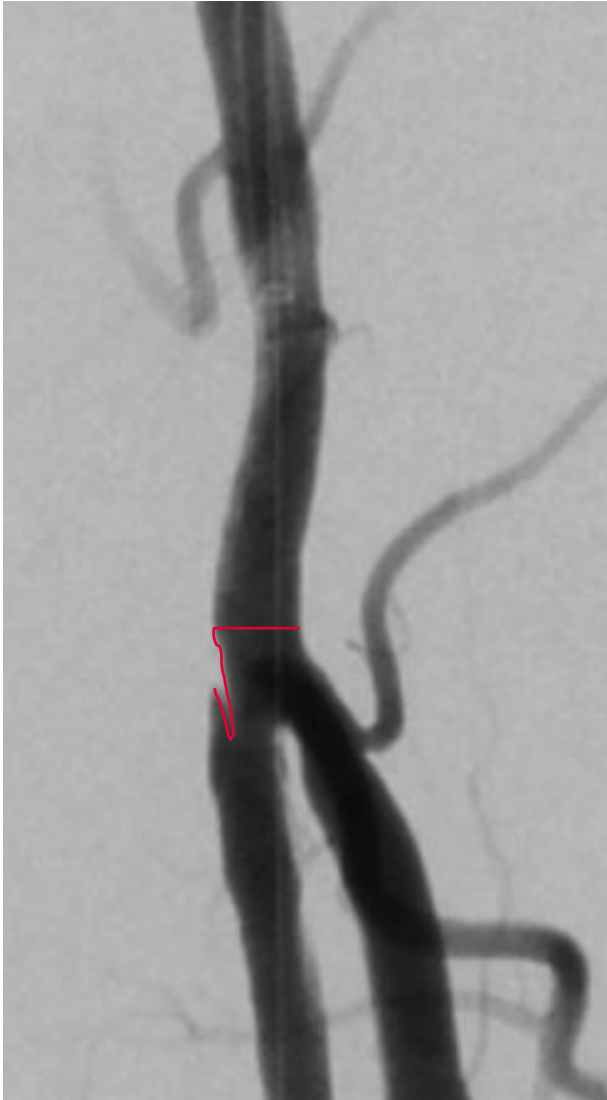
83 y-old lady

- Extensive AV ulcers
- Diabetic
- Hypertensive
- Rest pain
- ABPI 0.3







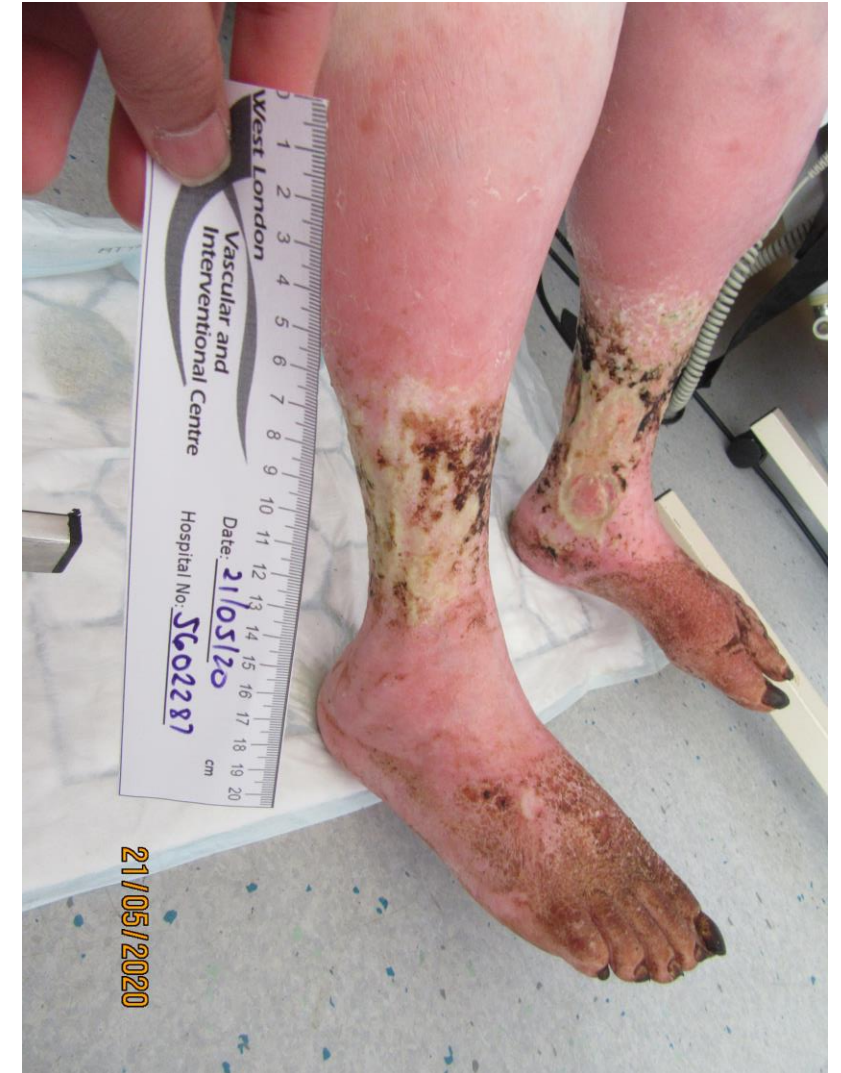

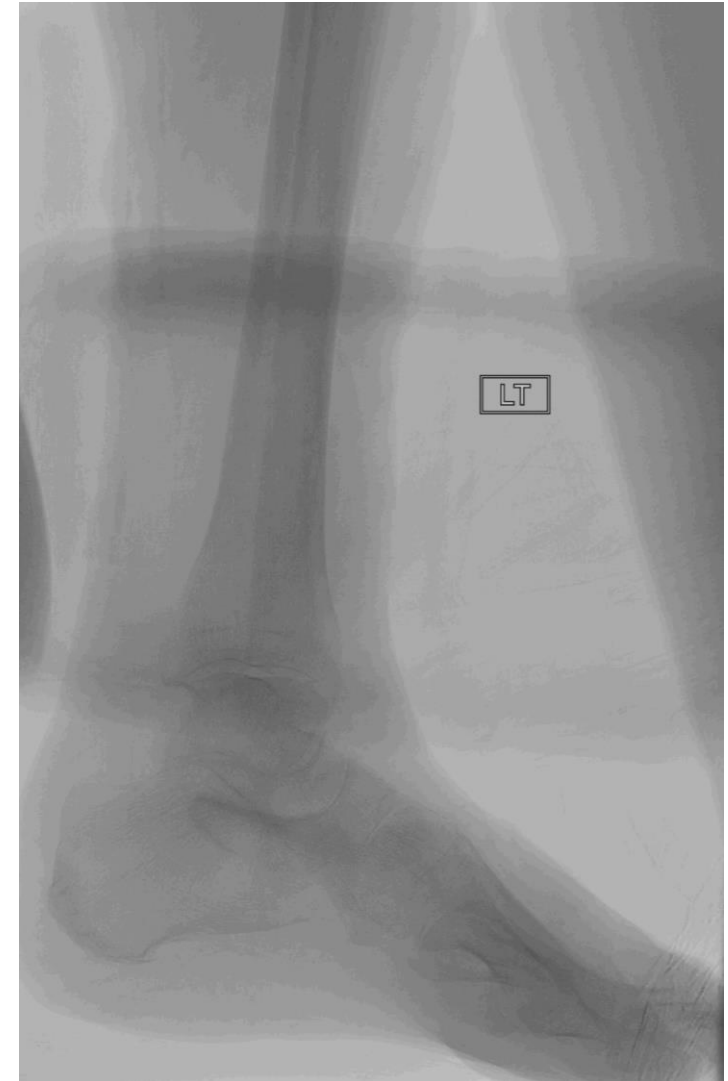
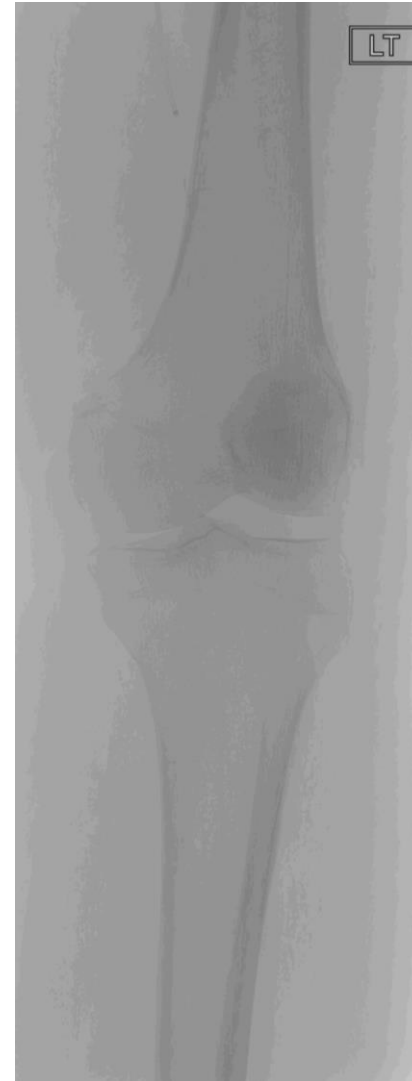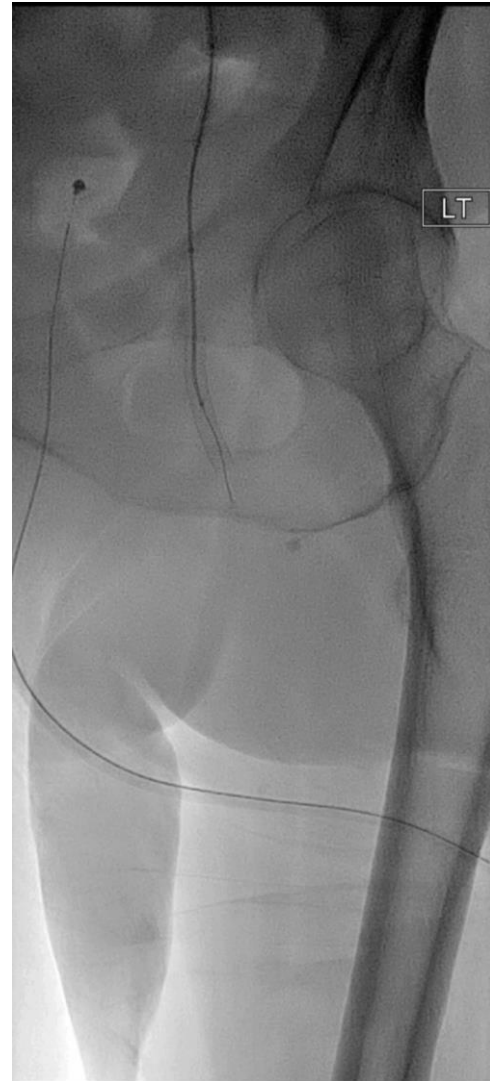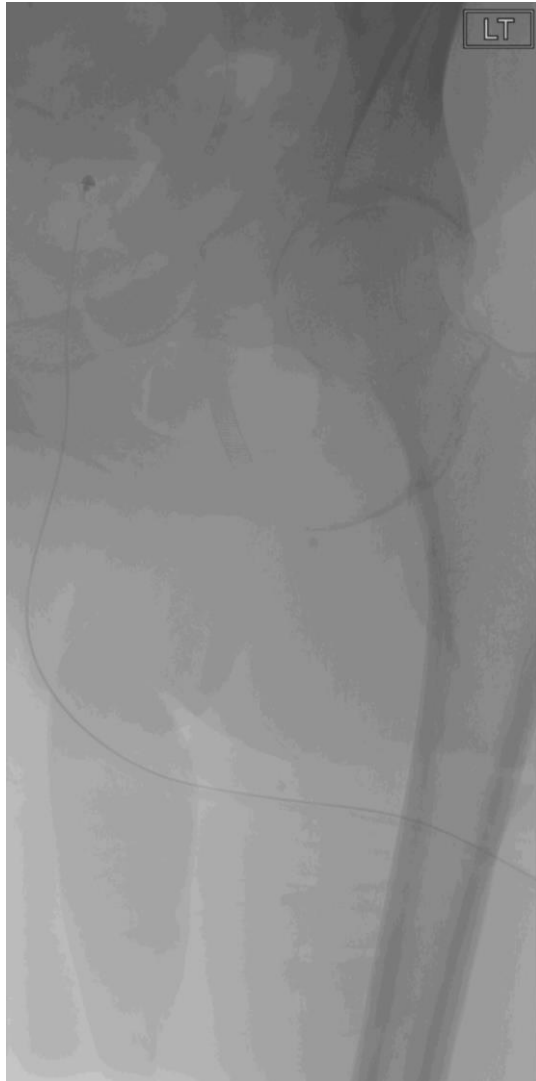


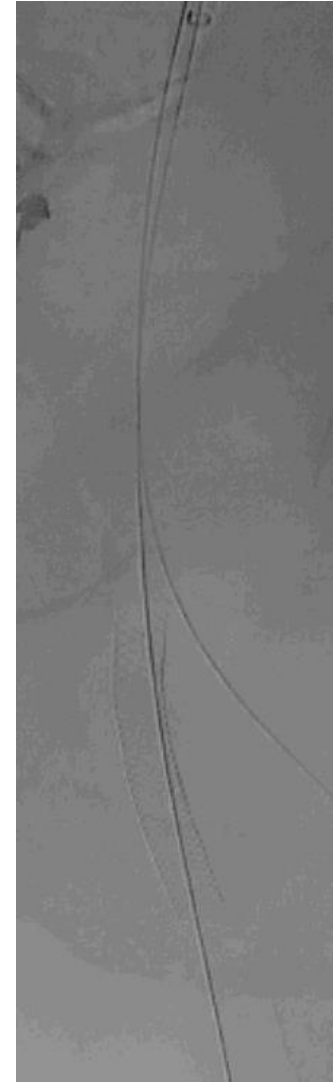
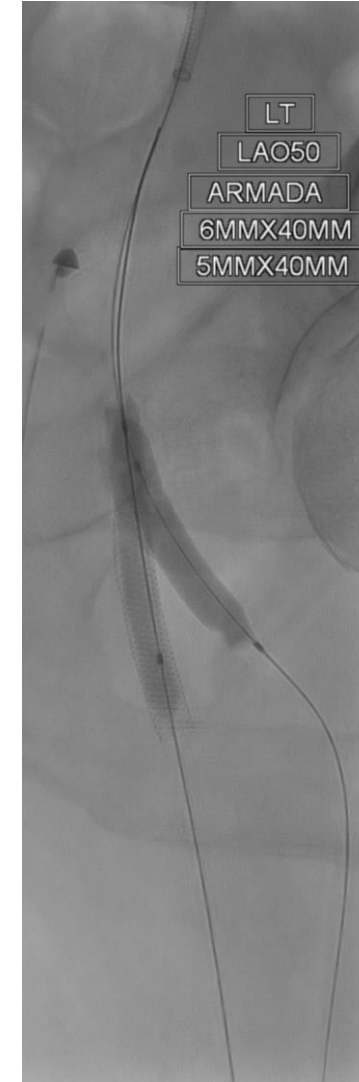
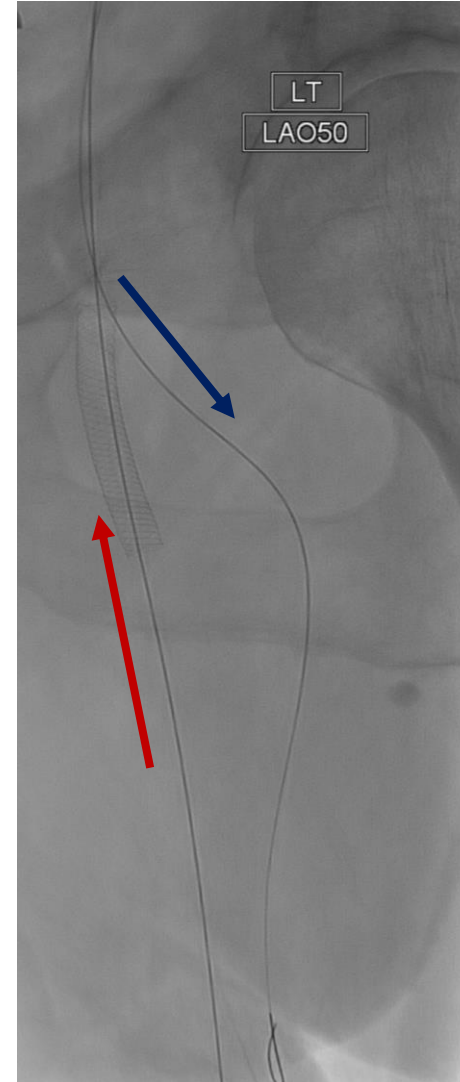
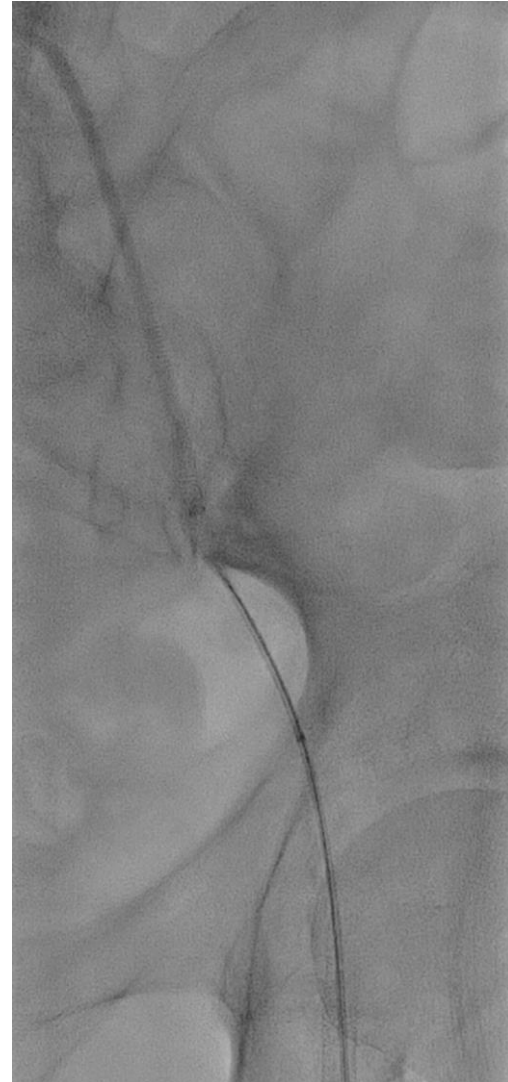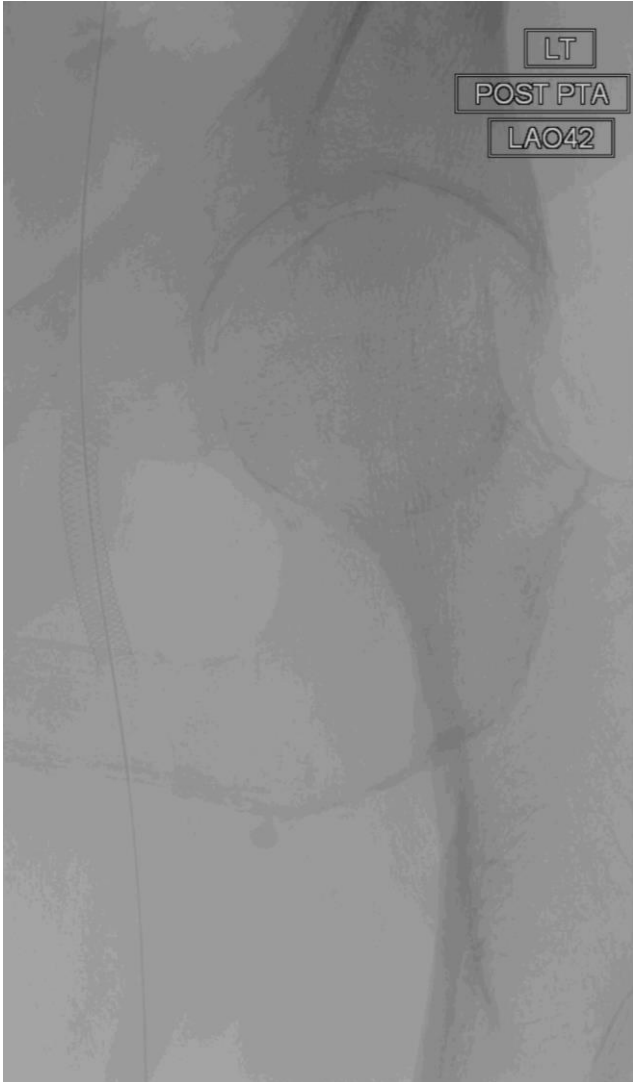
May 2020

Back to hospital with

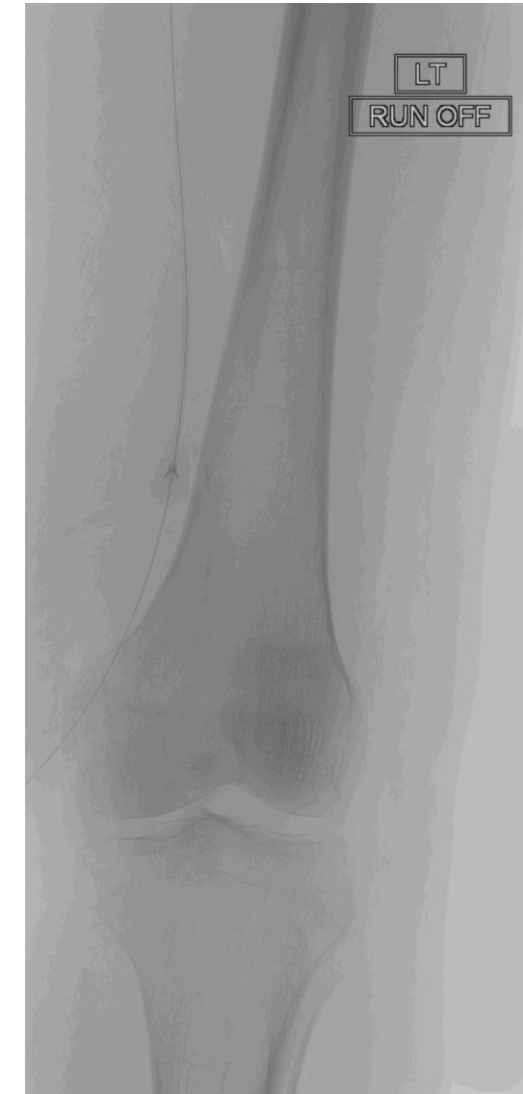
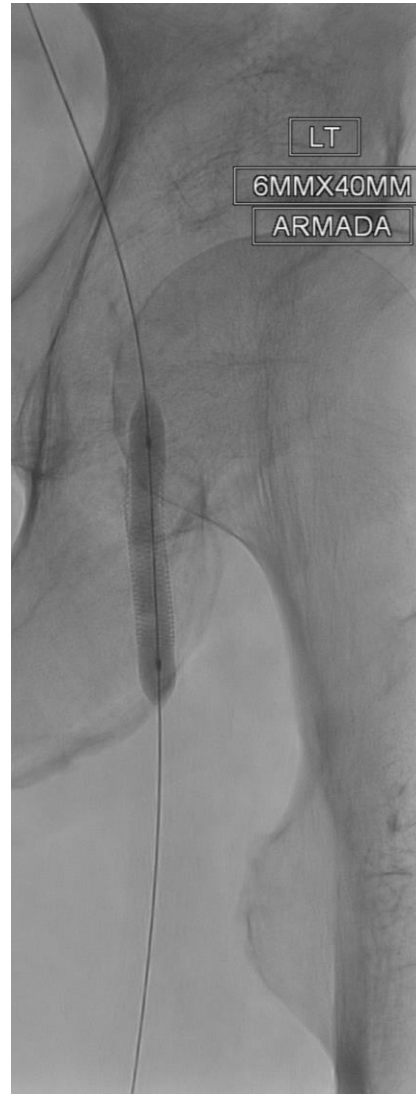
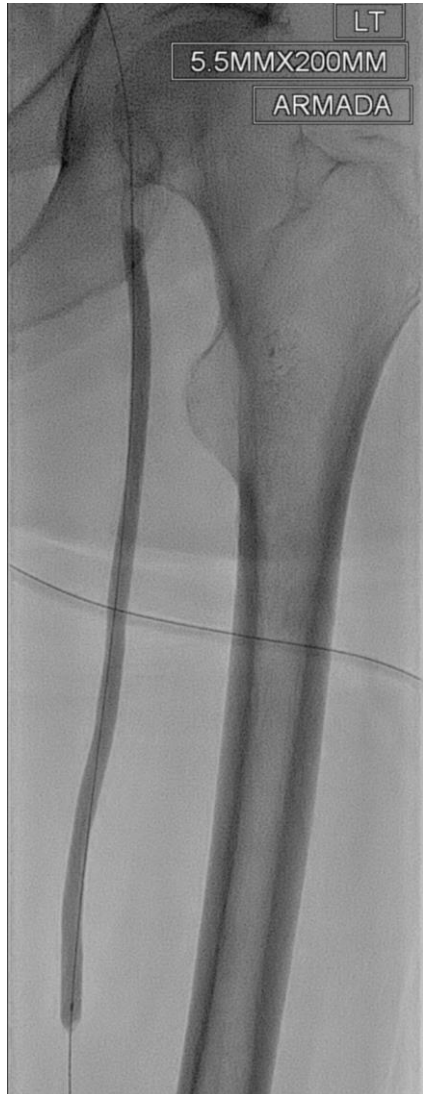
- Ulcers not healed
- ? CA breast / Lung met
- Rest pain
- L SFA reoccluded
- PFA severely stenotic

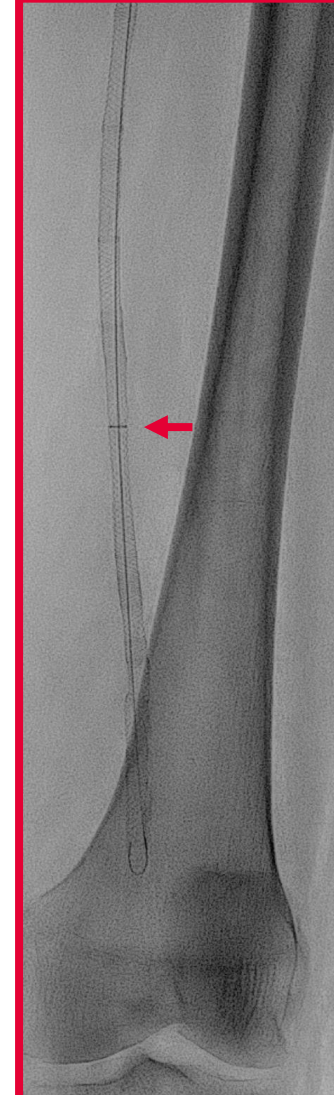

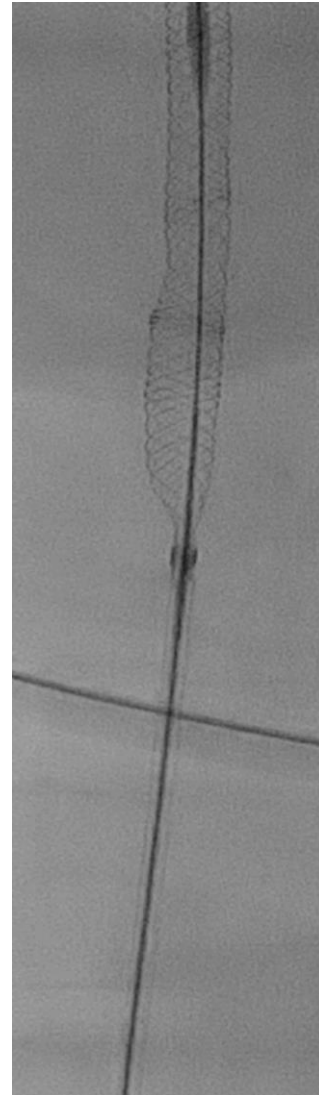
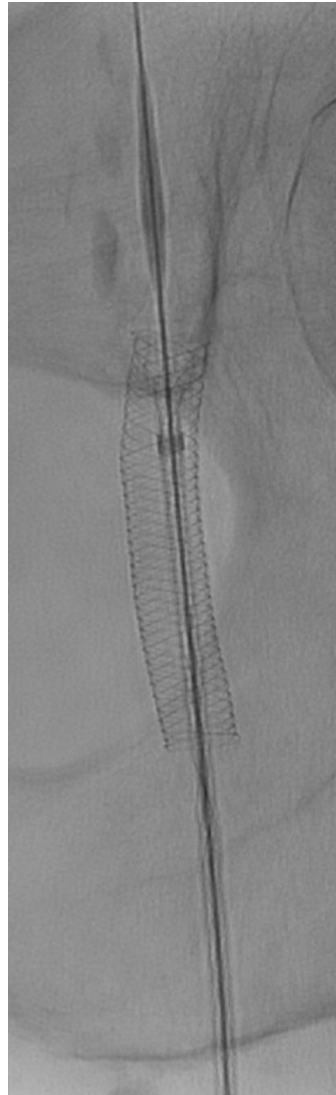
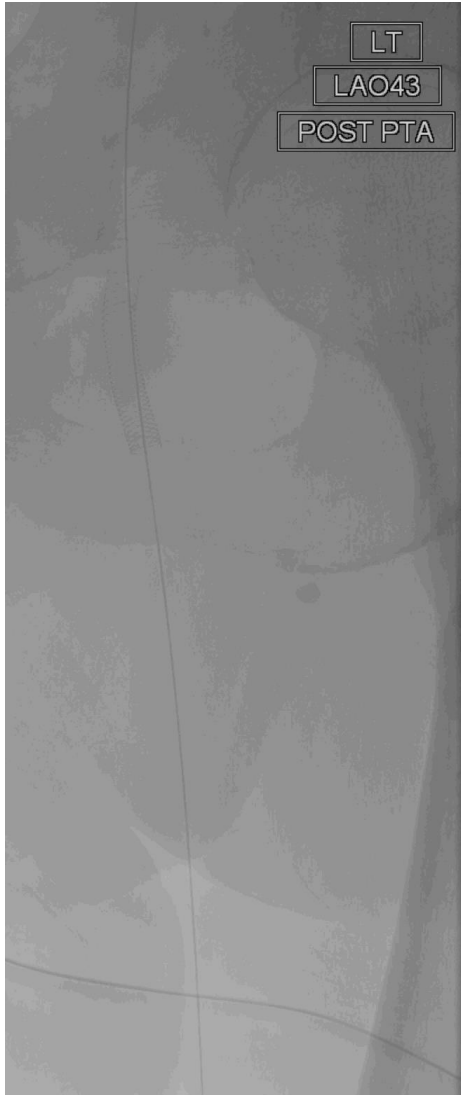














JACC: CARDIOVASCULAR INTERVENTIONS

© 2020 BY THE AMERICAN COLLEGE OF CARDIOLOGY FOUNDATION

PUBLISHED BY ELSEVIER

VOL. ■, NO. ■, 2020

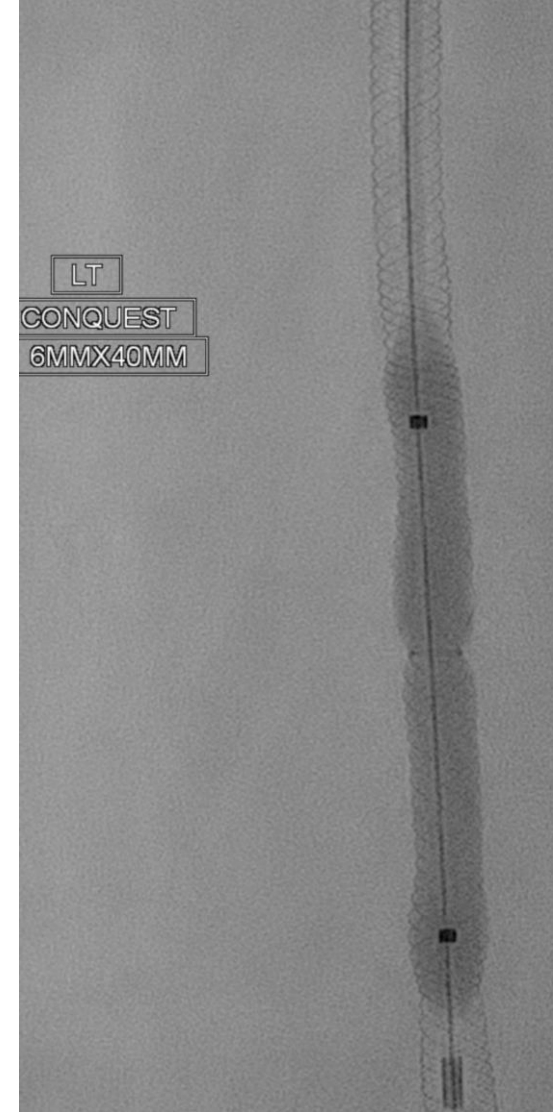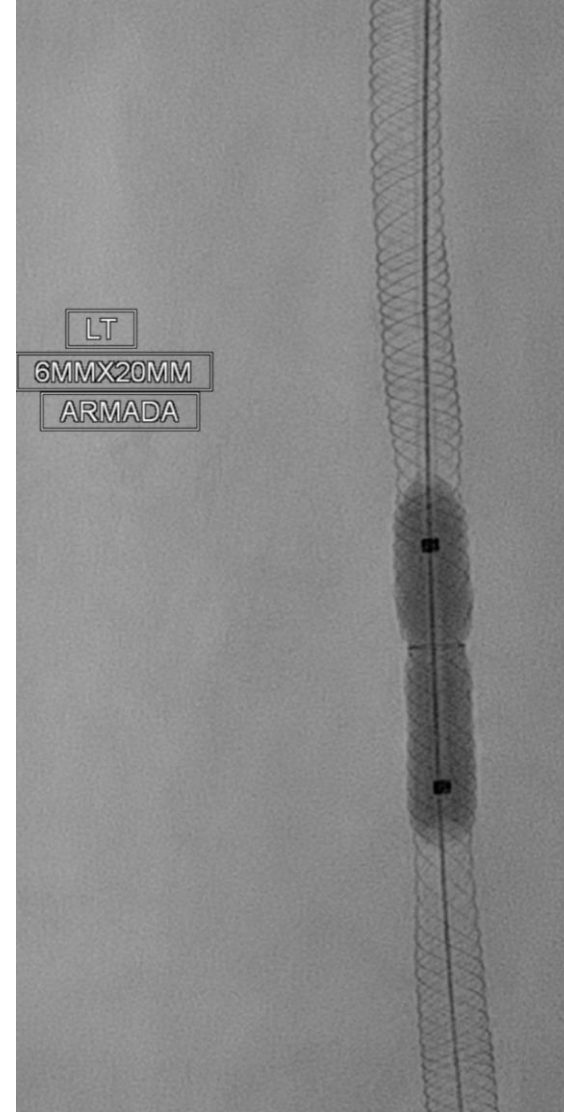

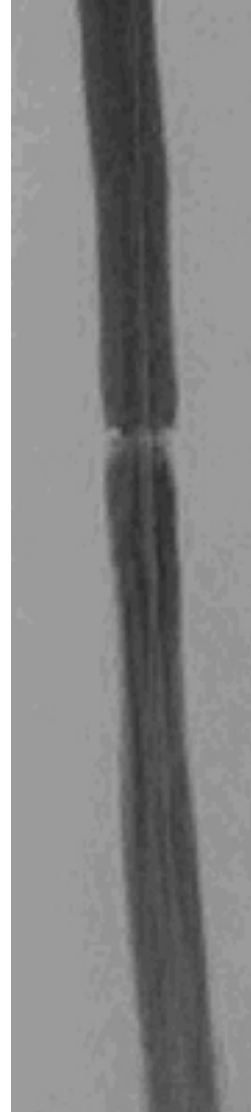
## IMAGES IN INTERVENTION

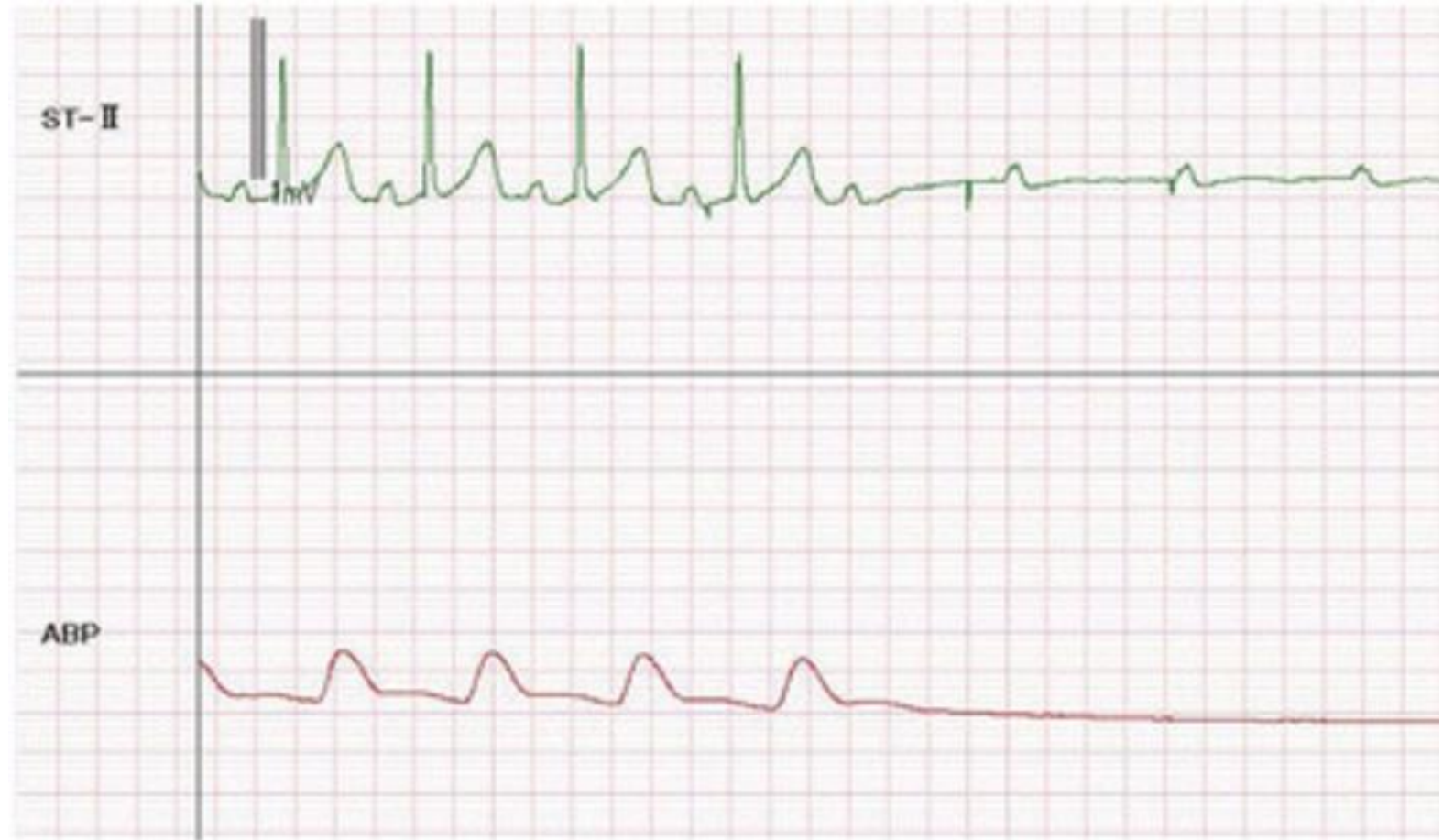
---

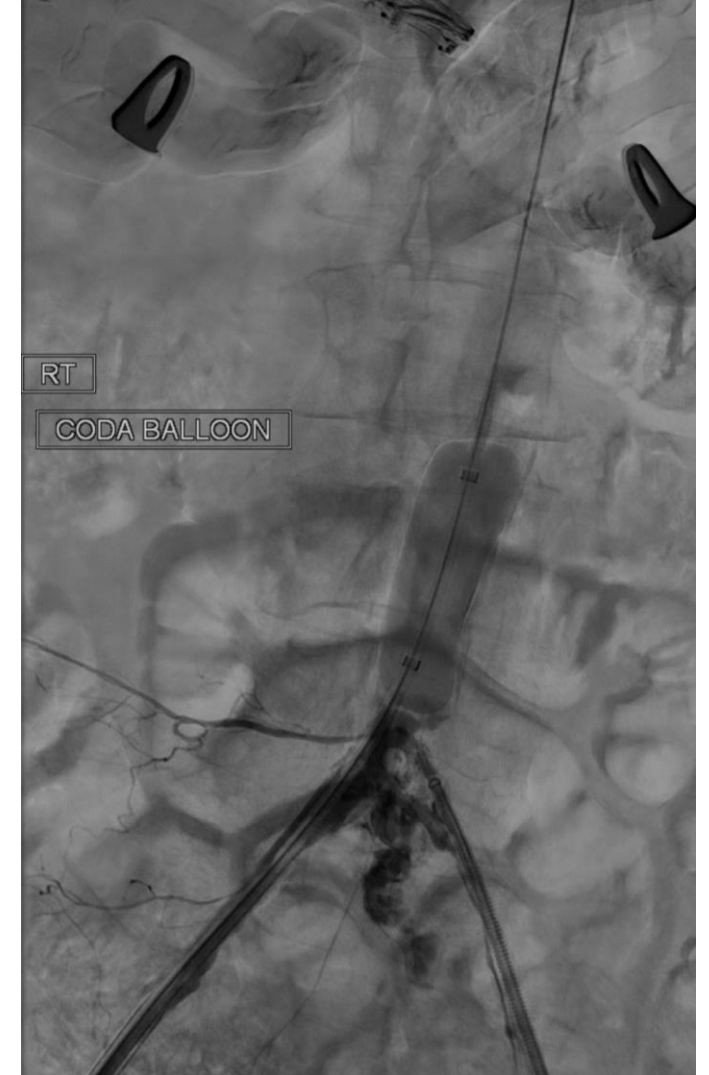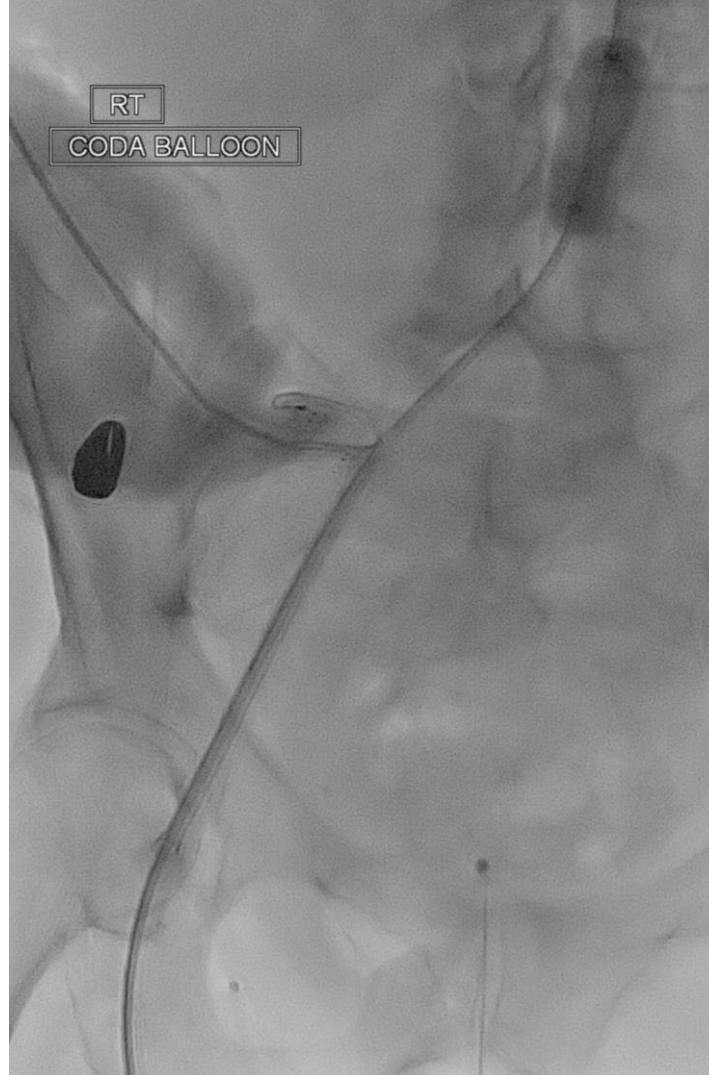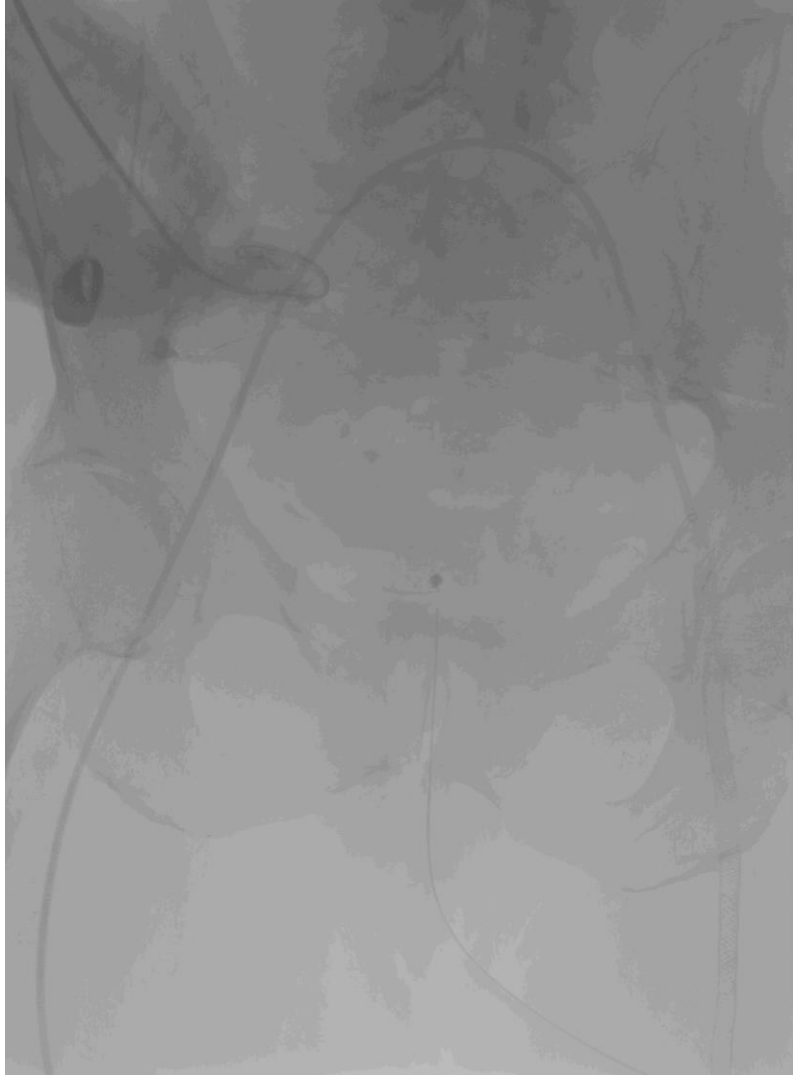
# Invagination of an Interwoven Nitinol Stent During Femoropopliteal Placement

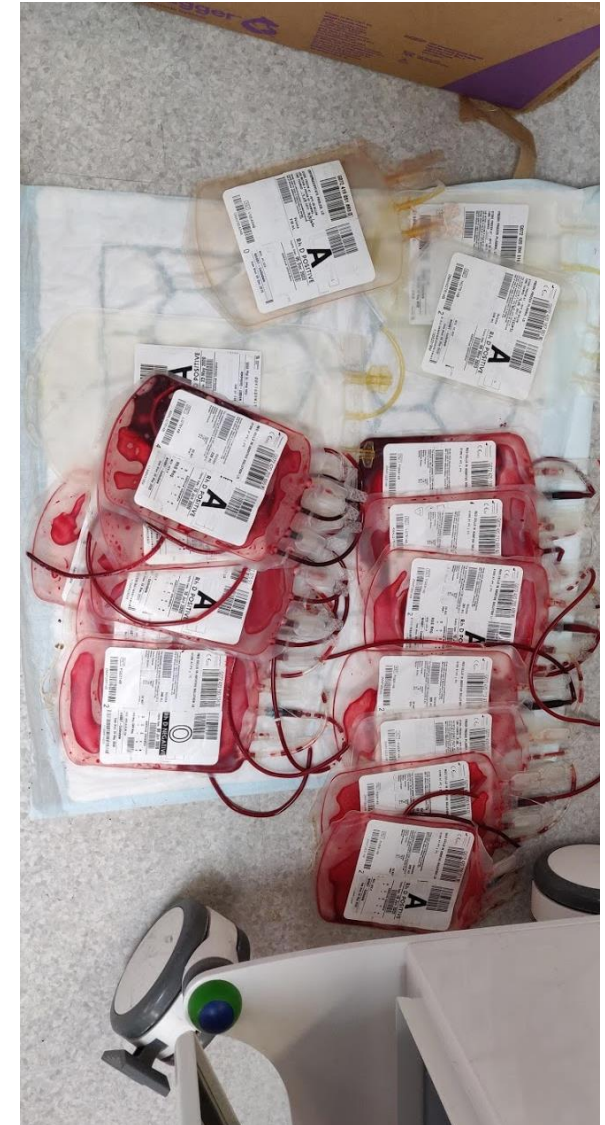
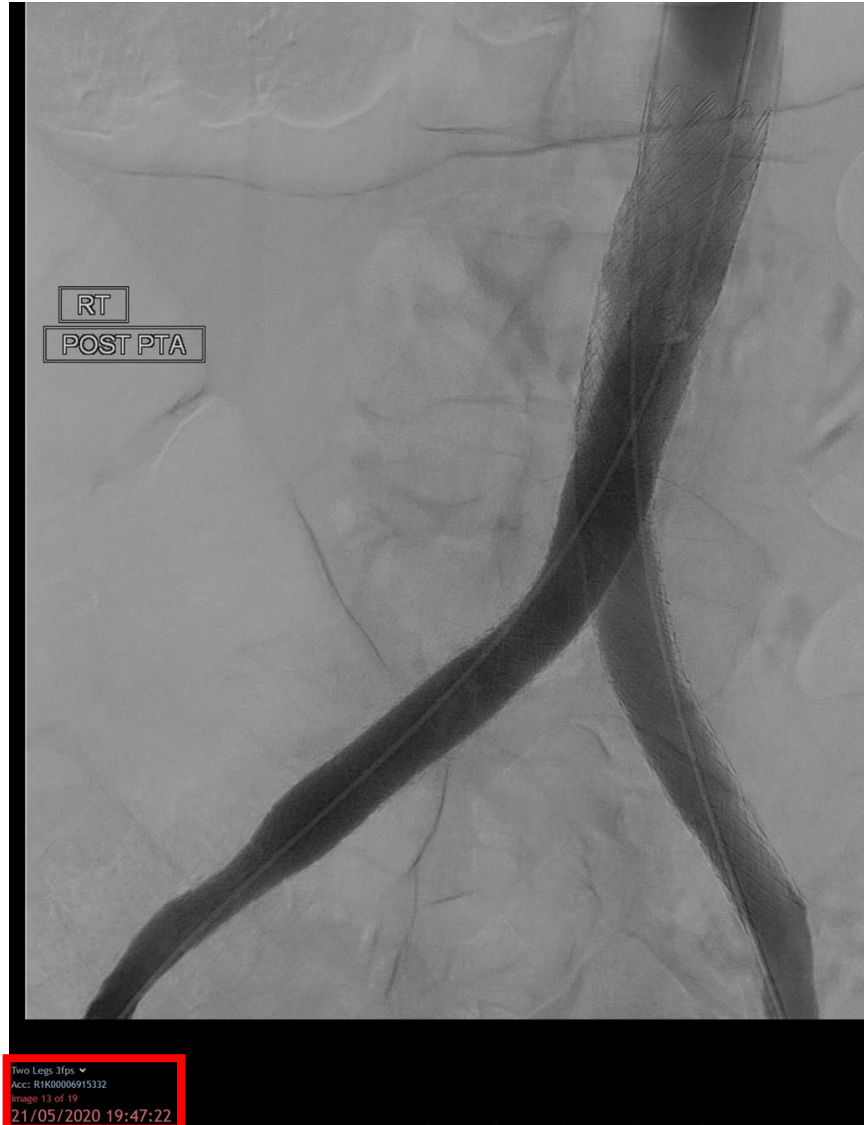
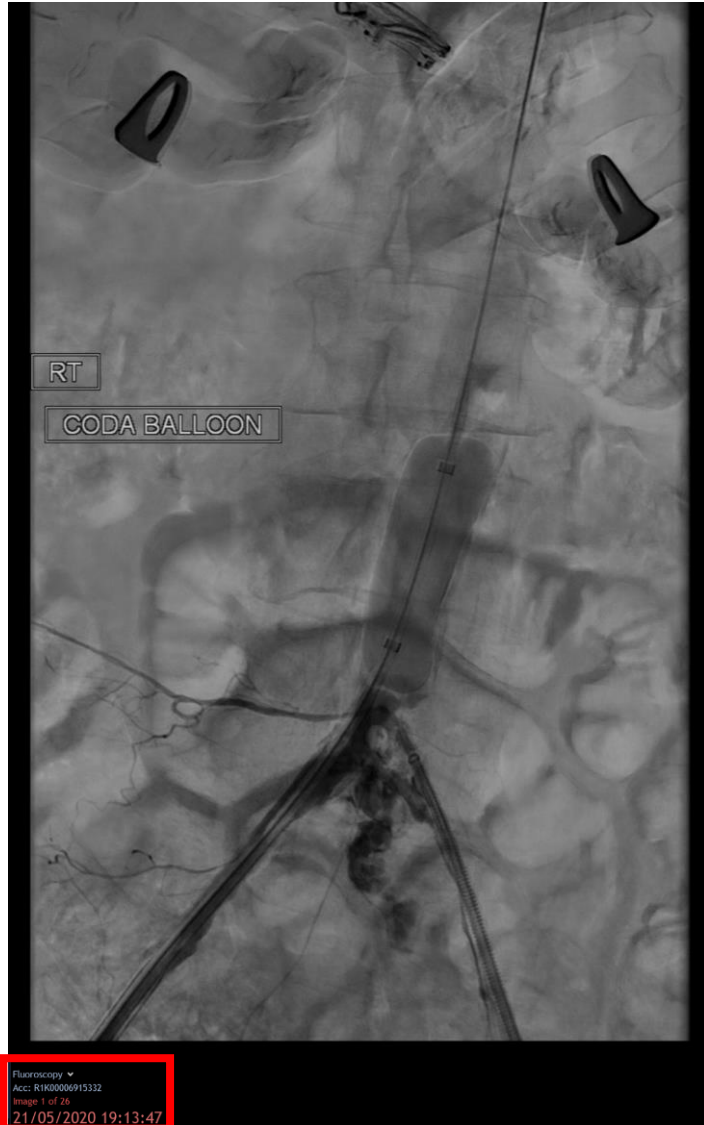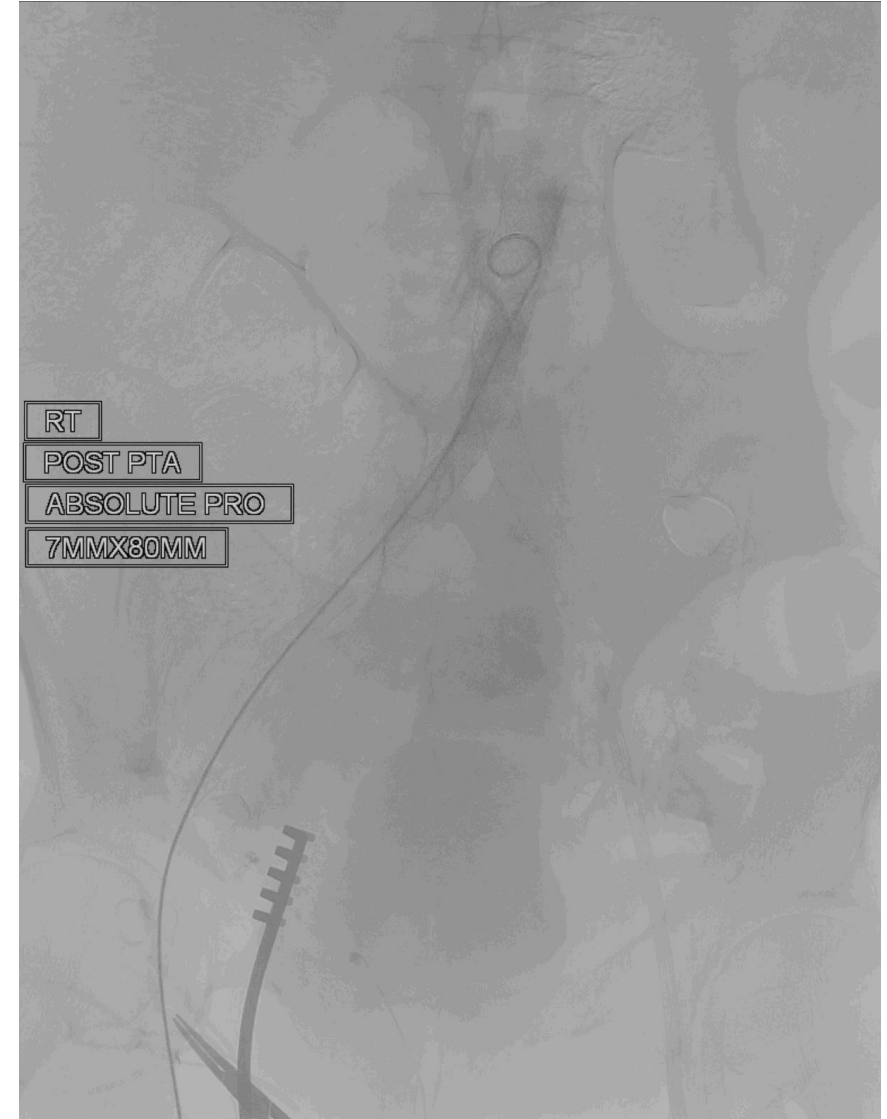

Tatsuya Nakama, MD, Kotaro Obunai, MD, Makio Muraishi, MD, Shunsuke Kojima, MD, Hiroyuki Watanabe, MD



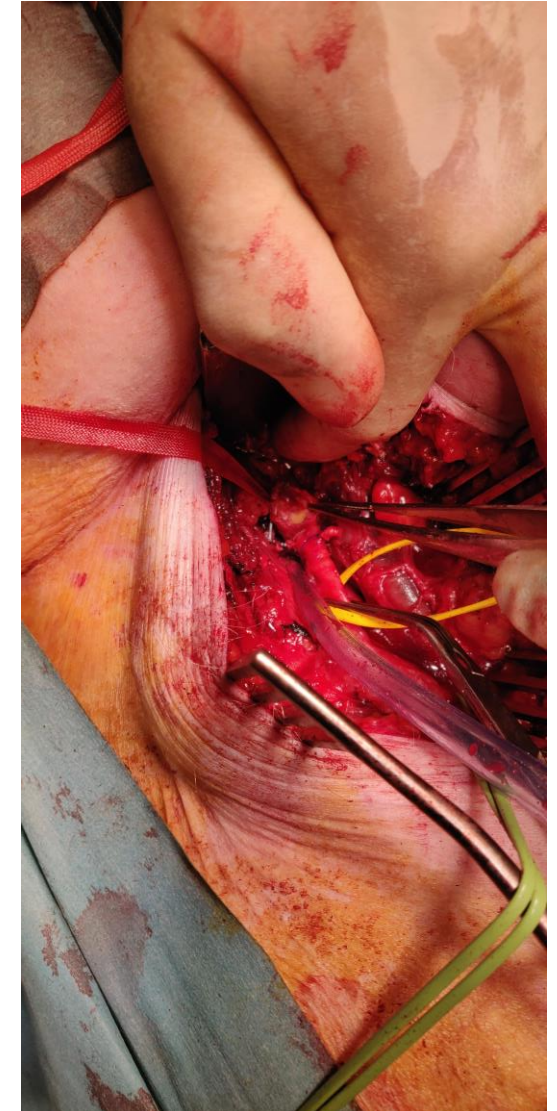
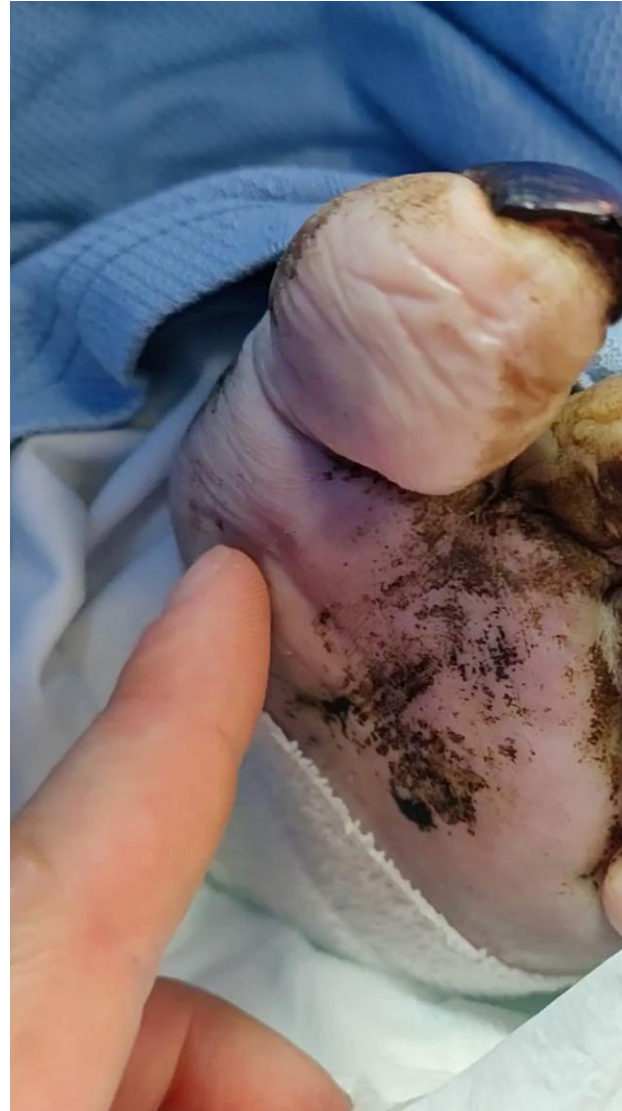

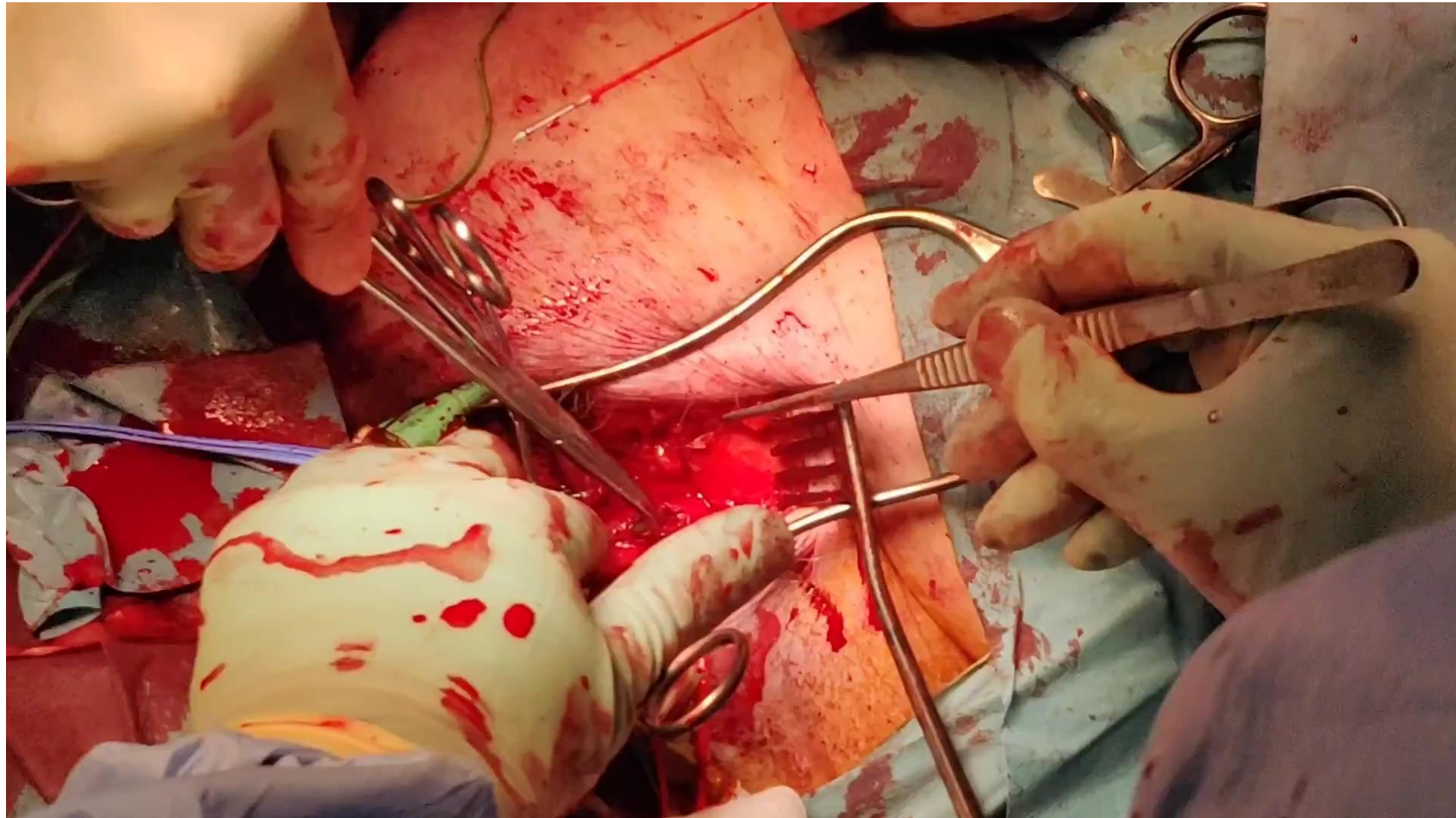


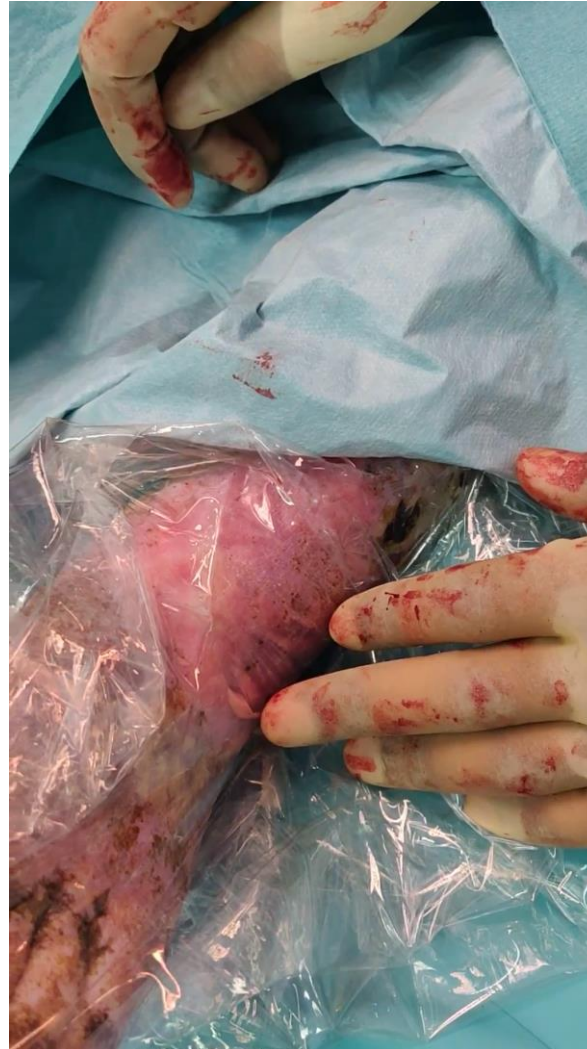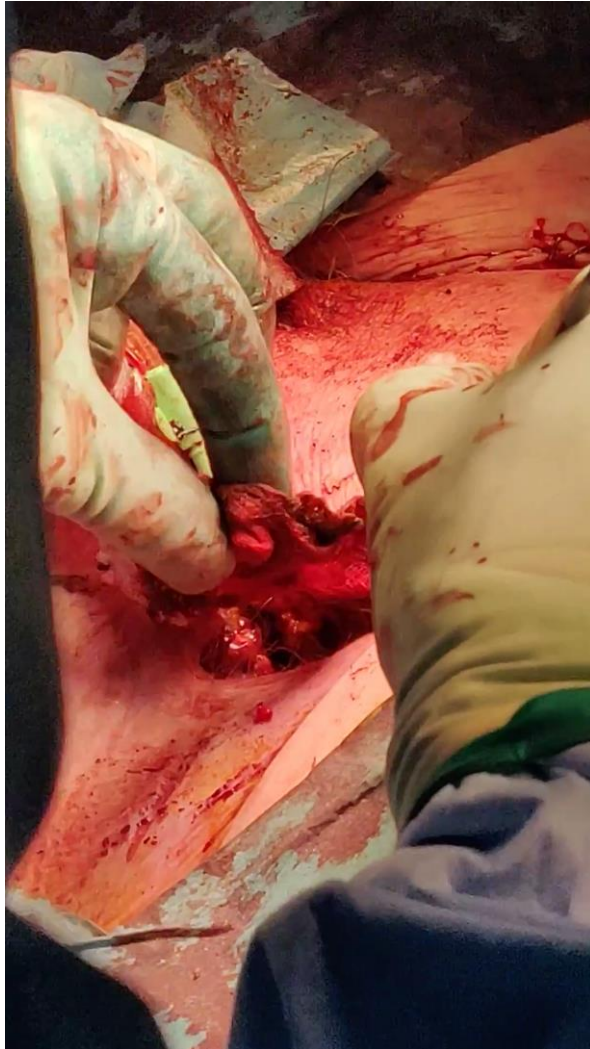














## INVAGINATION IN SUPERA STENT CAN RARELY HAPPEN

- THE STENT DOES NOT ONLY INVAGINATE BUT IT ALSO TWISTS PERMANENTLY DAMAGING ONE OR MORE WIRES
- IMPOSSIBLE TO BREAK THE THREE LAYERS OF STRUTS EVEN WITH HIGH PRESSURE BALLOON (ALSO PROVED BY OUR BENCH TEST)
- TO PULL WITH A SLIGHTLY OVERSIZED BALLOON WORKS BUT IT COULD BE RISKY WHEN IN CROSSOVER
- TO PULL OUT THE STENT PARTIALLY DEPLOYED IS FEASIBLE (done in 6 cases) BUT HIGHLY PREFERABLE WHEN LESS THAN 50% IS ALREADY DEPLOYED

