

B O R D E A U X

# PERSPECTIVES

Friday, June 17, 2022

My most didactic/ nightmarish cas and my most promising and innovative technique

## ORGANIZATION

Eric Ducasse & Maxime Sibé


## CONTACT & INFORMATION

ademarconnay@divine-id.com  
[www.congresperspectives.com](http://www.congresperspectives.com)





# Cauchemar en Finistère... Chirugiens à la pointe



Bahaa NASR  
CHU Cavale Blanche, Brest





## **Disclosure**

Speaker name:

**Bahaa NASR**

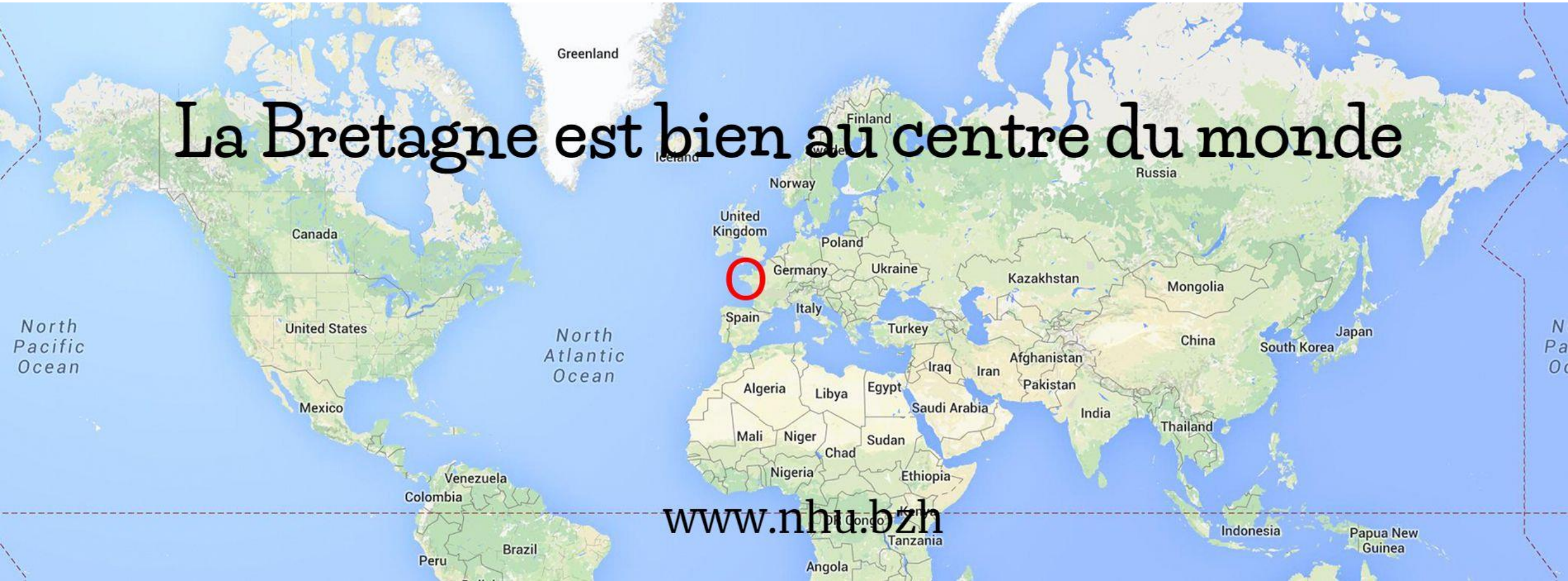I have the following potential conflicts of interest to report:

**Consulting: Biotronic, Medtronic, Gore**



Le Parisien

La Bretagne est bien au centre du monde



[www.nhu.bzh](http://www.nhu.bzh)



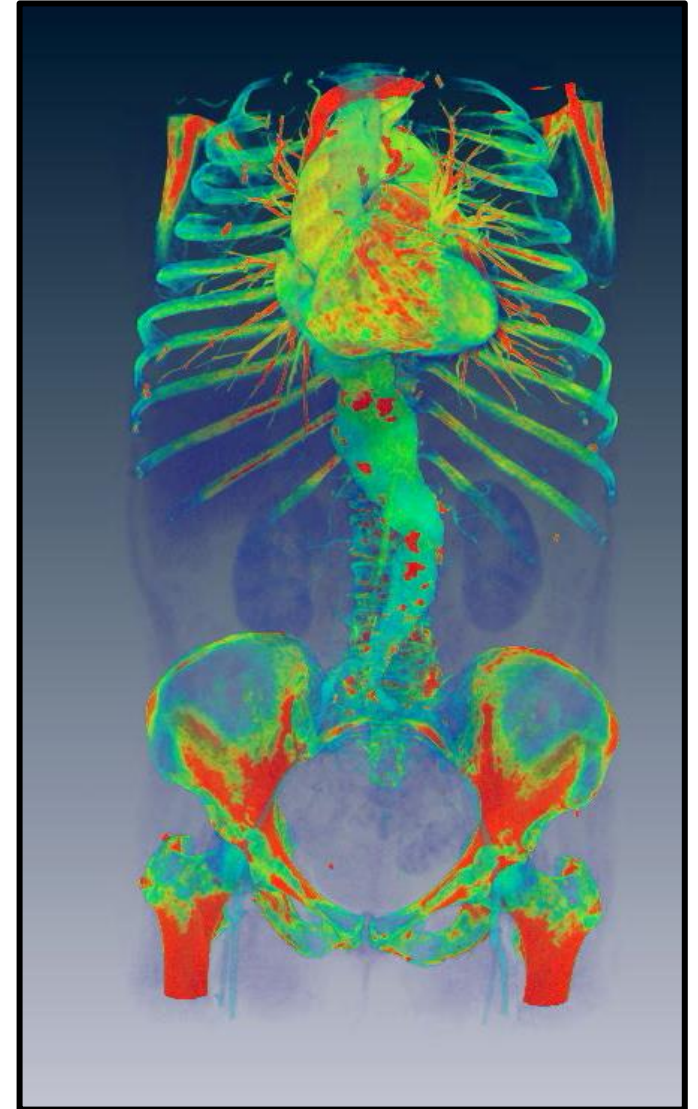
## **My worst case of limb arteries endovascular repair**

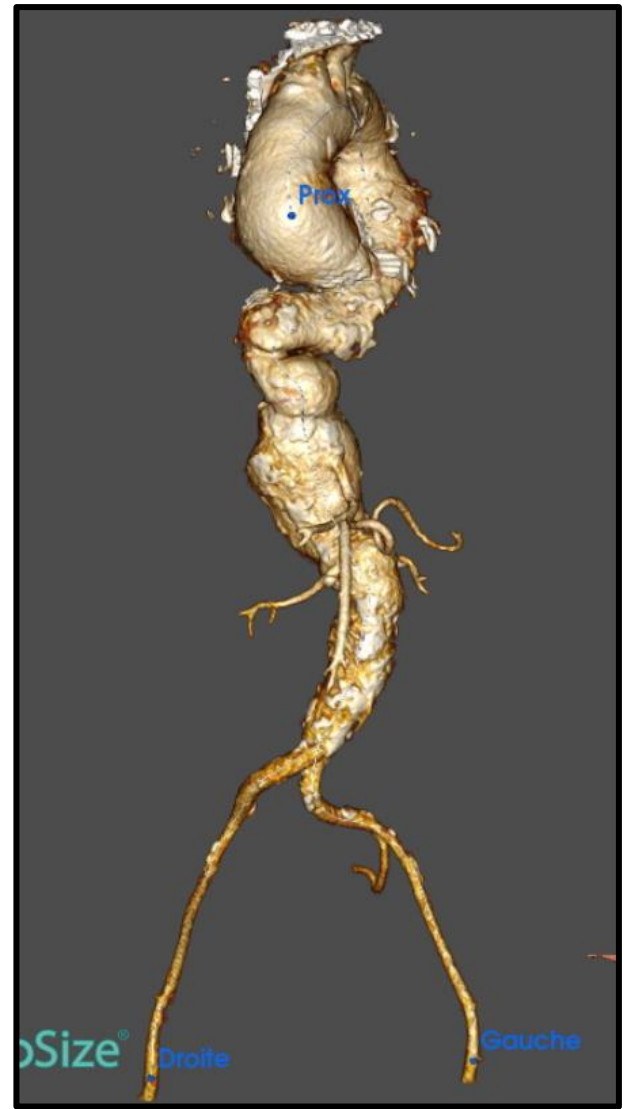
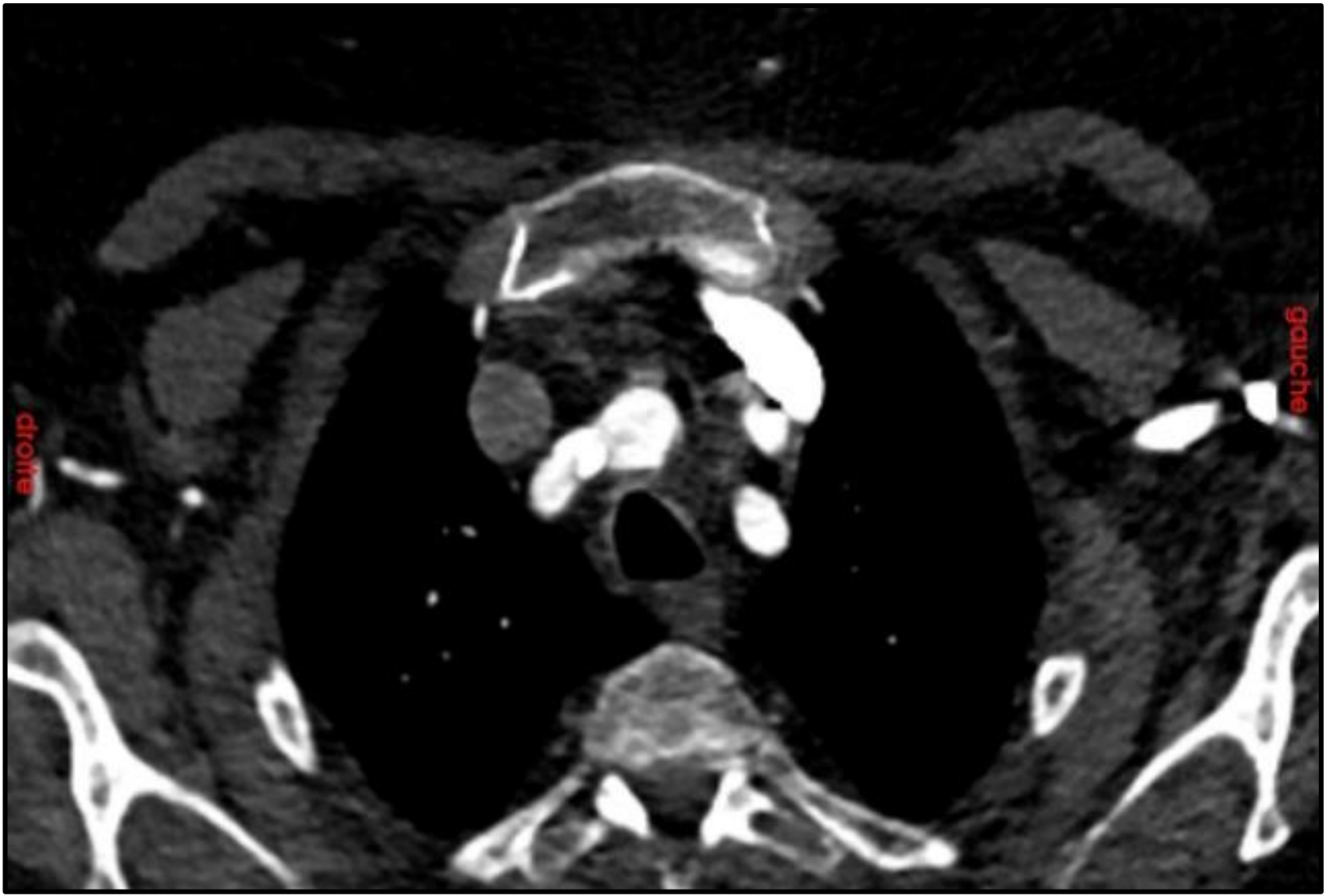

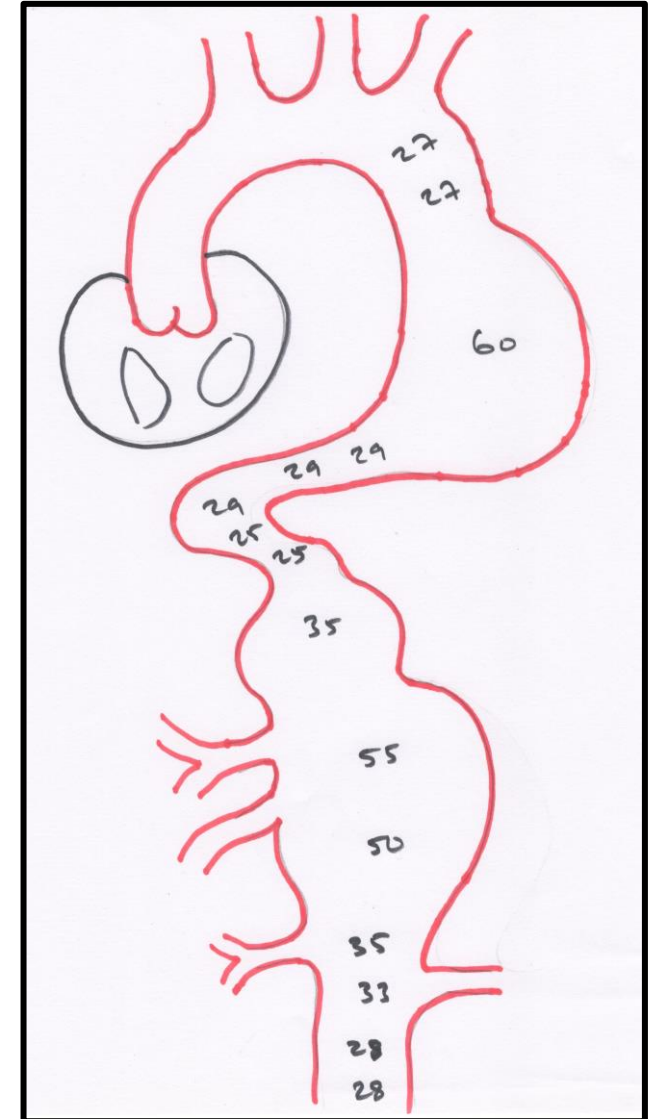

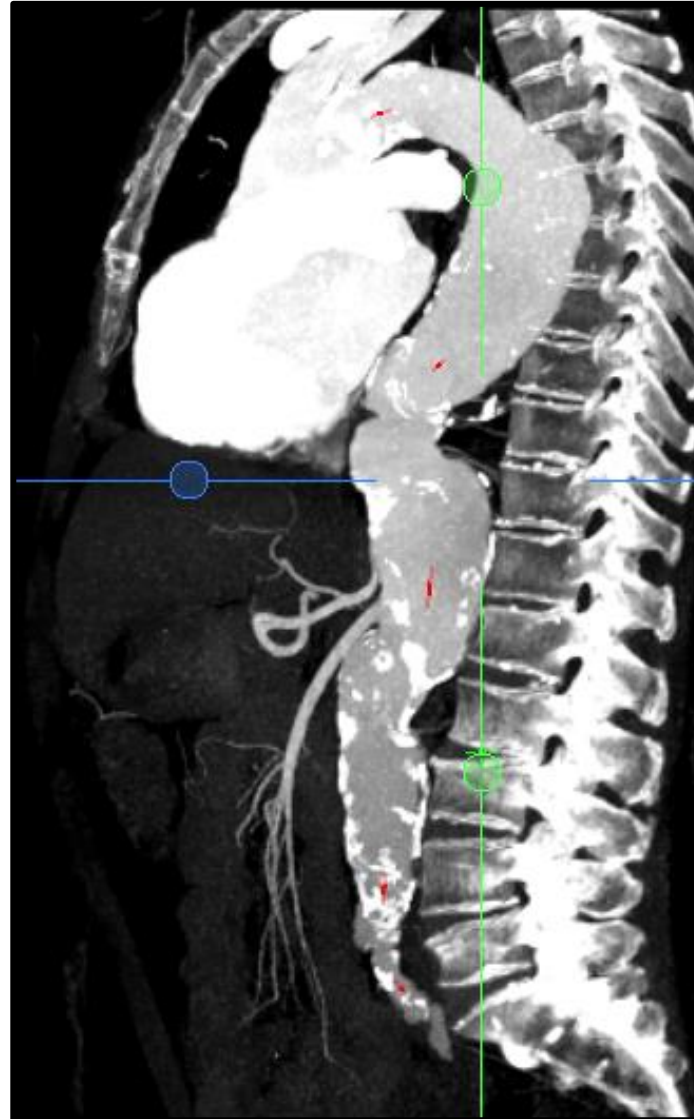
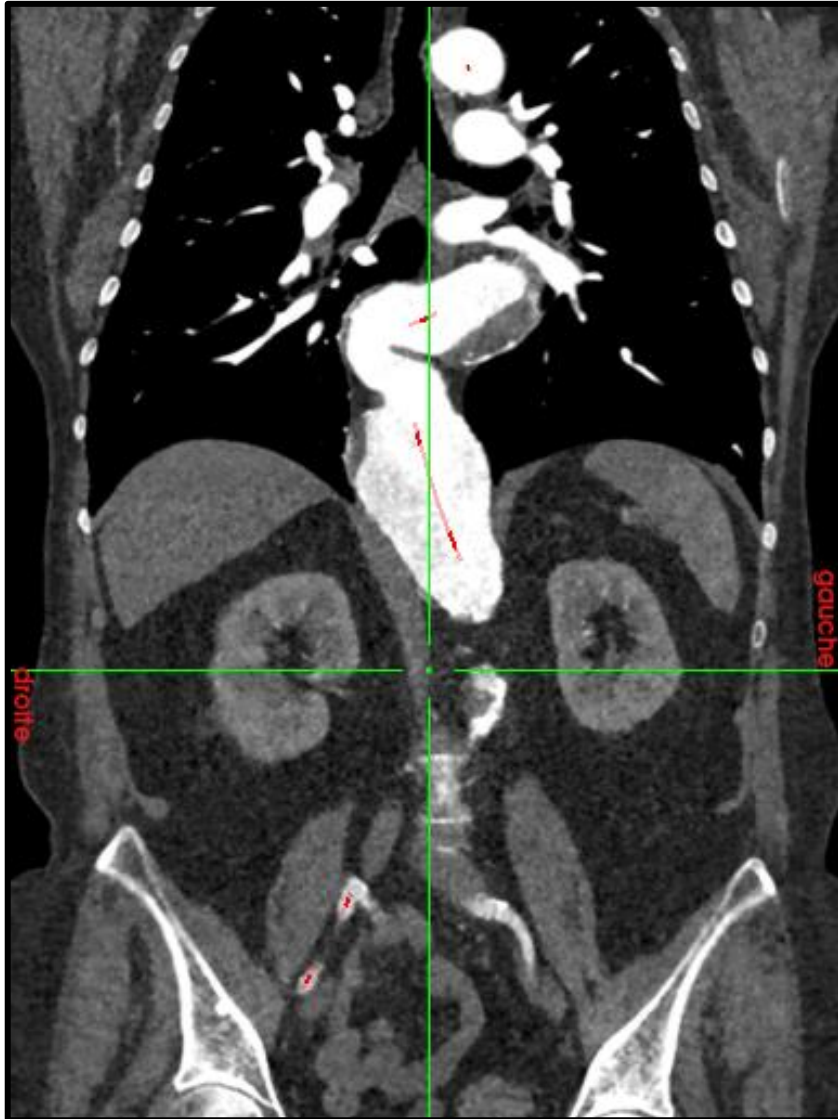## Case presentation

- 65 y.o. female patient,
- Thoraco-abdominal aneurysm
- Past history of:
  - Hypertension
  - Dyslipidemia
  - Active smoker
  - COPD





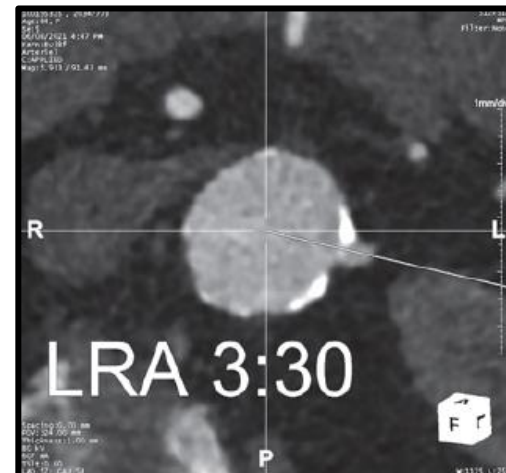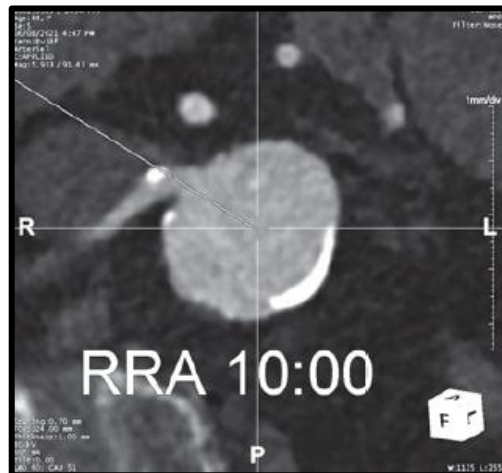

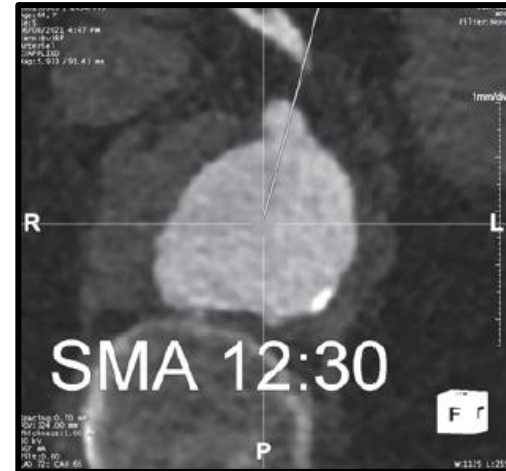
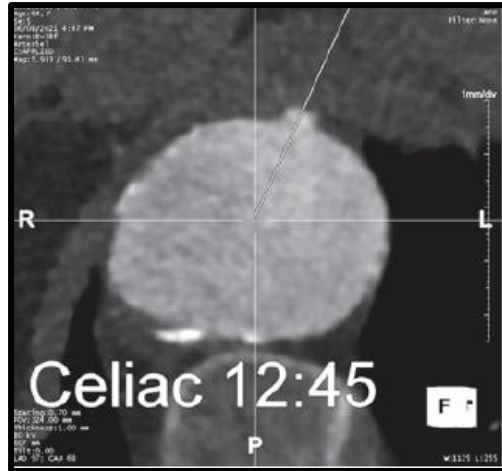

# B O R D E A U X PERSPECTIVES 2022



## June Friday 17

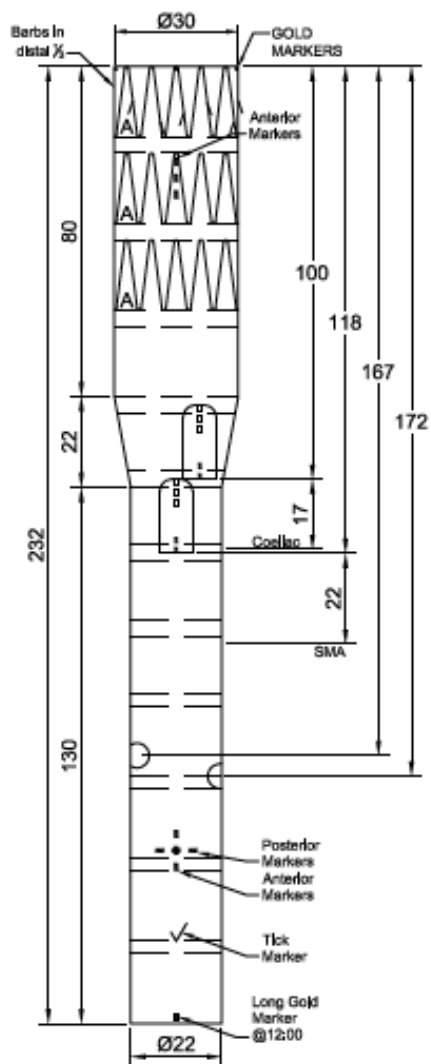




What is your strategy ?

- A: Open surgery
- B: Endovascular treatment
- C: Hybrid surgery
- D: High volume Aortic center





**INTERNAL/EXTERNAL SIDEBRANCH #1**

DIAMETER: 8mm  
LENGTH: 18mm  
DIST FROM PROX EDGE: 100mm  
CLOCK: 1:00

**INTERNAL/EXTERNAL SIDEBRANCH #2**

DIAMETER: 8mm  
LENGTH: 18mm  
DIST FROM PROX EDGE: 118mm  
CLOCK: 12:00

**REINFORCED SMALL FENESTRATION #1**

DIAMETER: 6mm  
DIST FROM PROX EDGE: 167mm  
CLOCK: 10:00  
IVD: 21mm

**REINFORCED SMALL FENESTRATION #2**

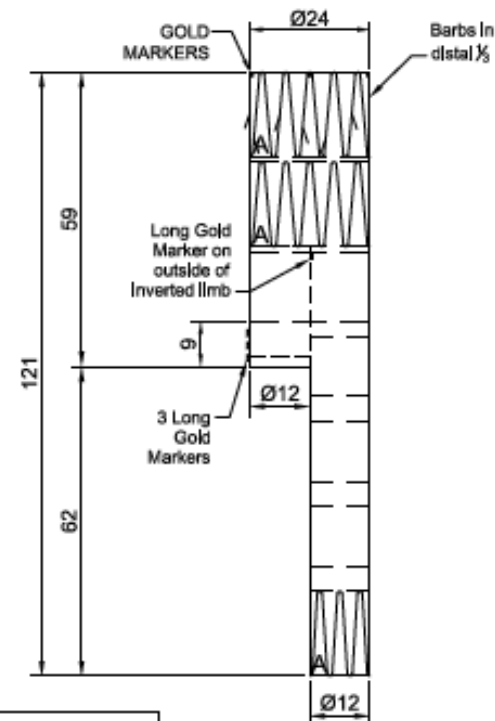
DIAMETER: 6mm  
DIST FROM PROX EDGE: 172mm  
CLOCK: 3:30  
IVD: 21mm

- SINGLE DIAMETER REDUCING TIES

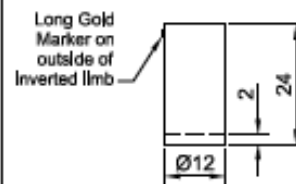
Plus:

Proximal Thoracic Component  
ZTA-P-32-201

**Left Side Introduction**



**INVERTED LIMB**



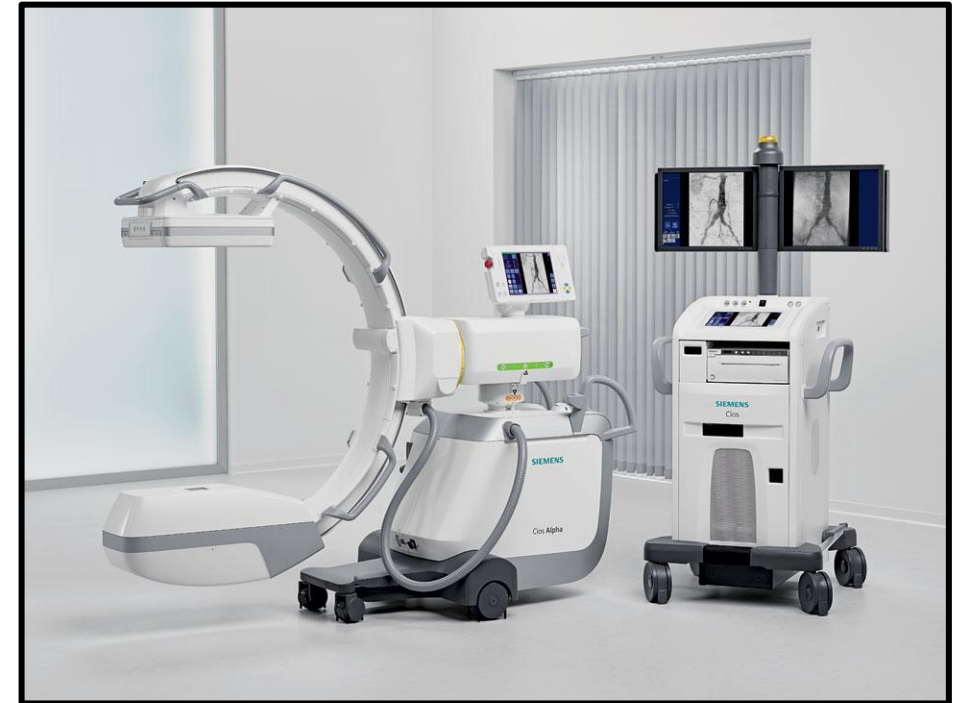Plus:

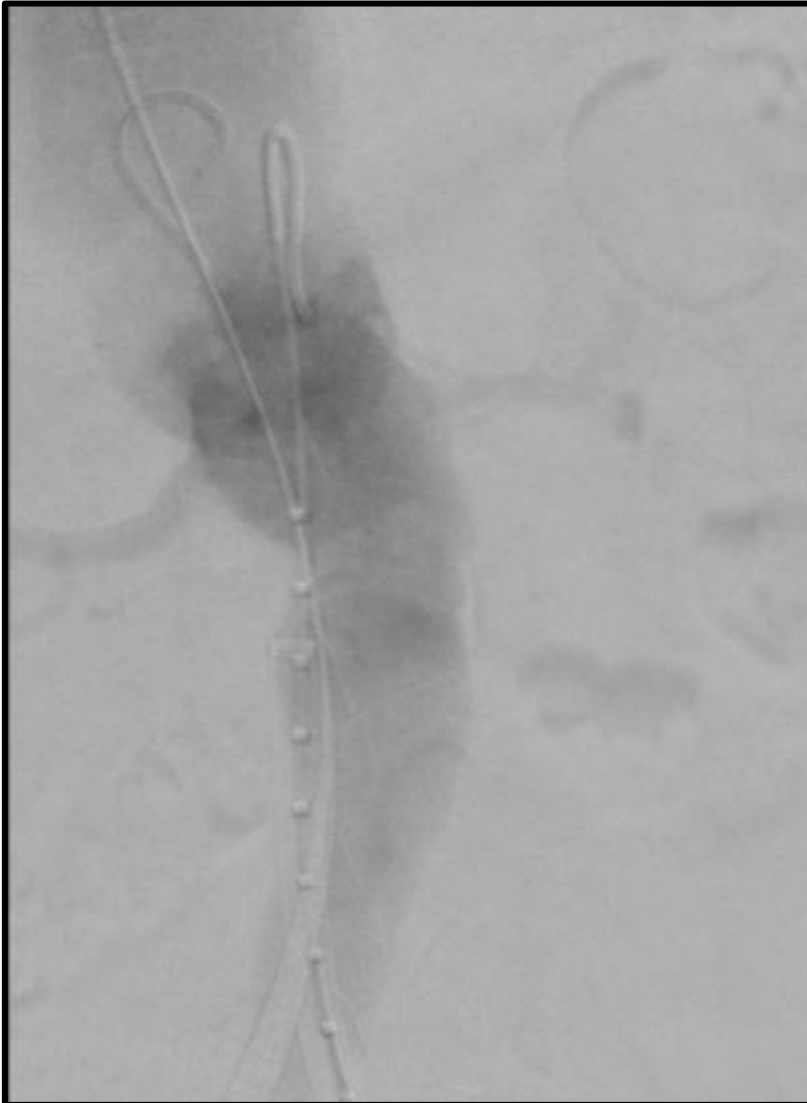
Contralateral Leg Extension  
ZISL-13-59



# Intervention

- Mobile C-Arm
- General Anesthesia
- Cerebrospinal fluid monitoring and drainage
- Bilateral percutaneous femoral approach





**10h00: Intervention beginning**

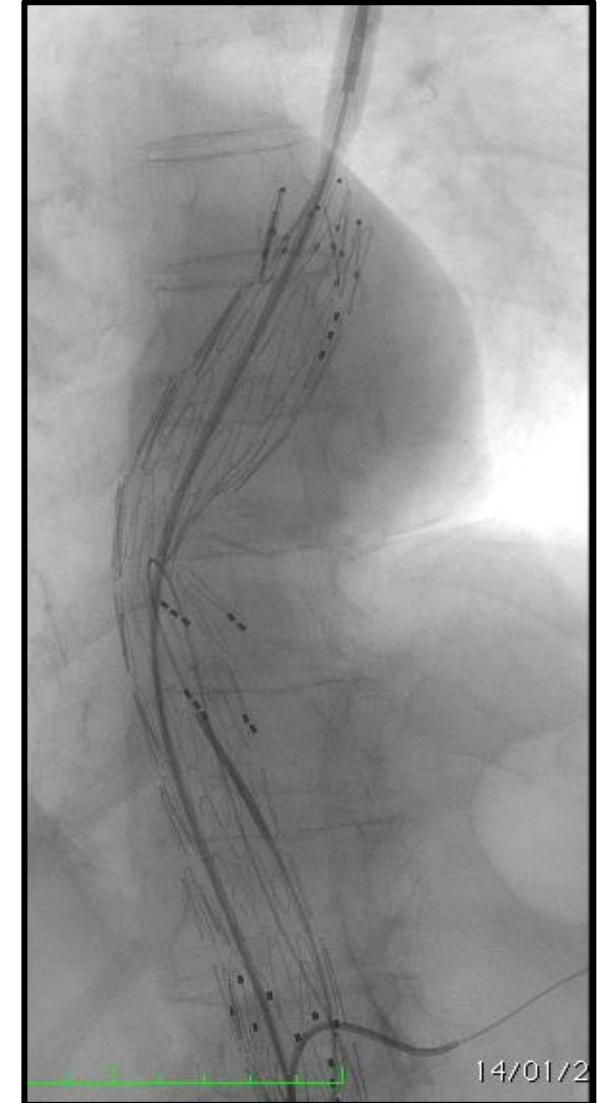
**10h30: Right renal catheterisation**

**12h00: LRA not catheterized**



**TIME IS TICKING**

**13h00: LRA stil not catheterized**


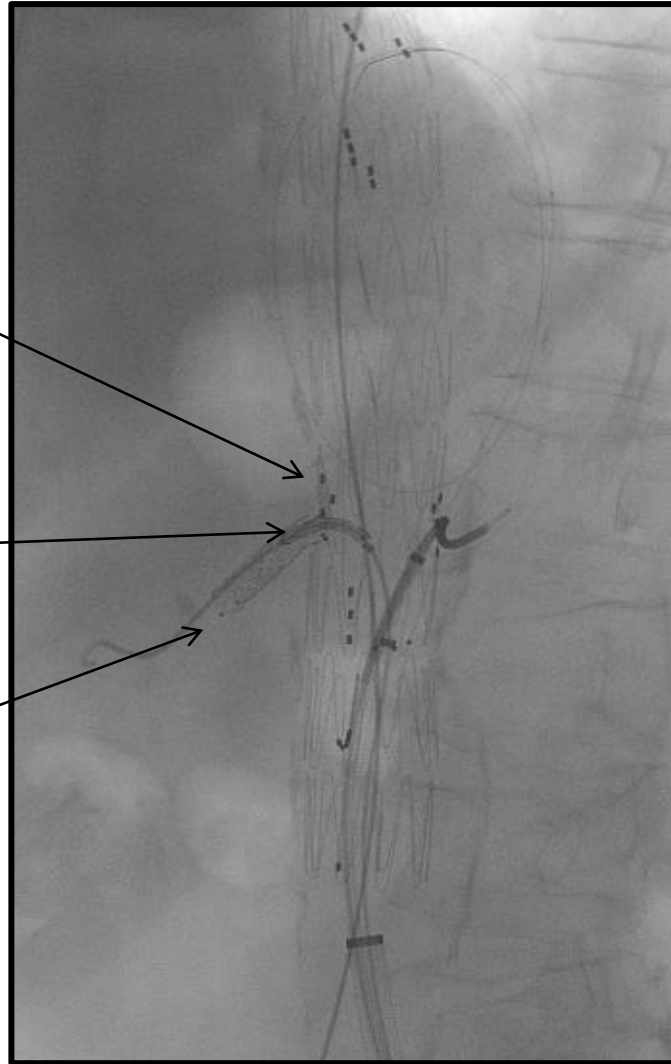

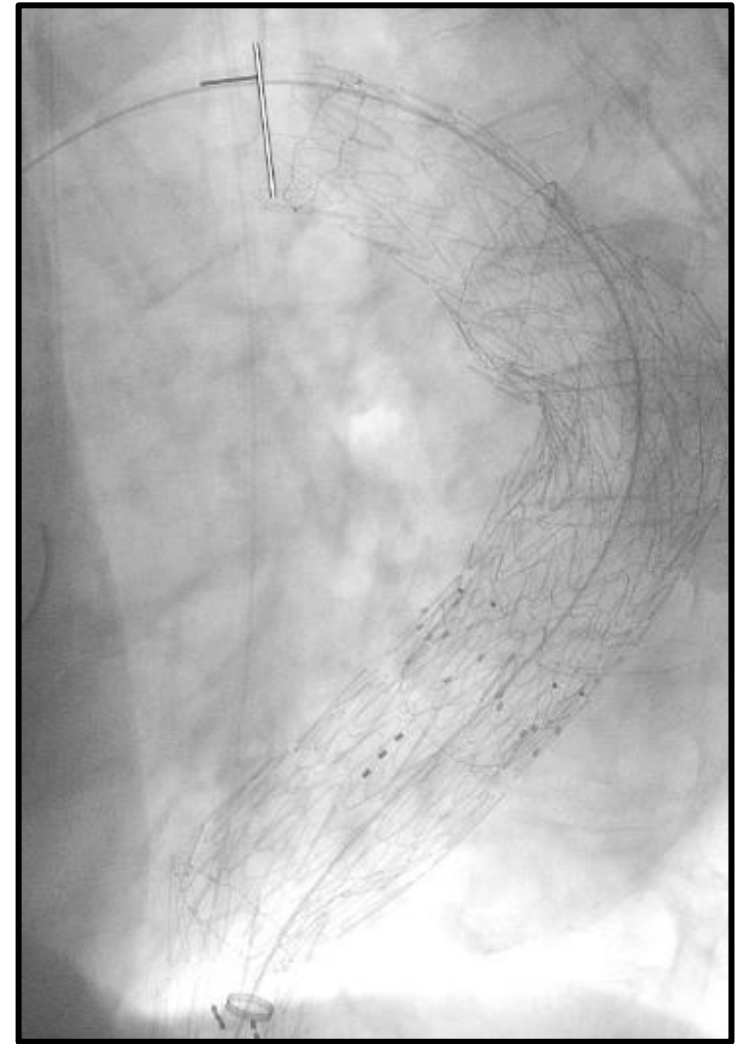
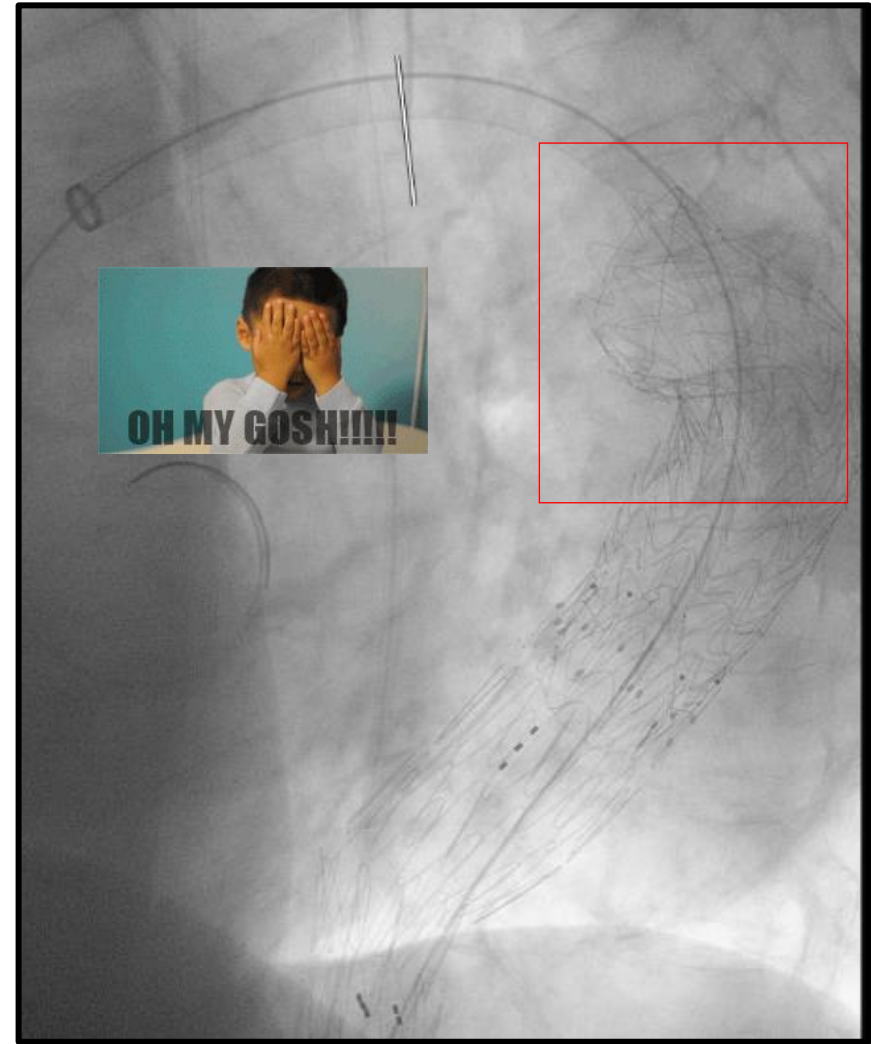
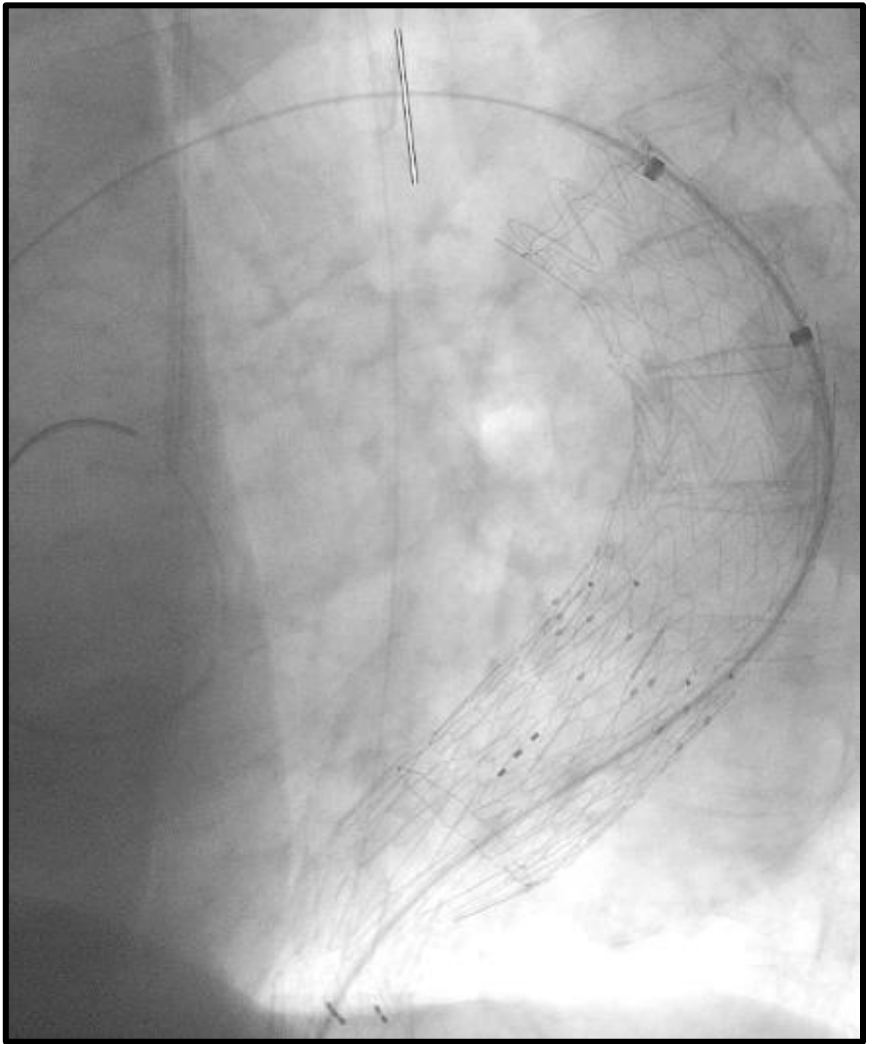


Reinforced small fenestration  
6 mm diameter

iCover 6 x 17 mm

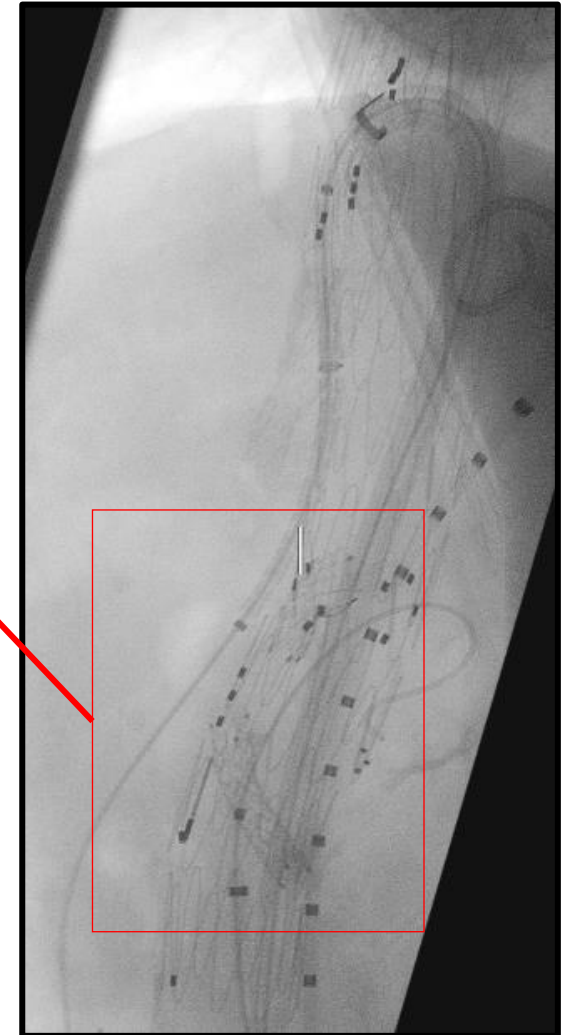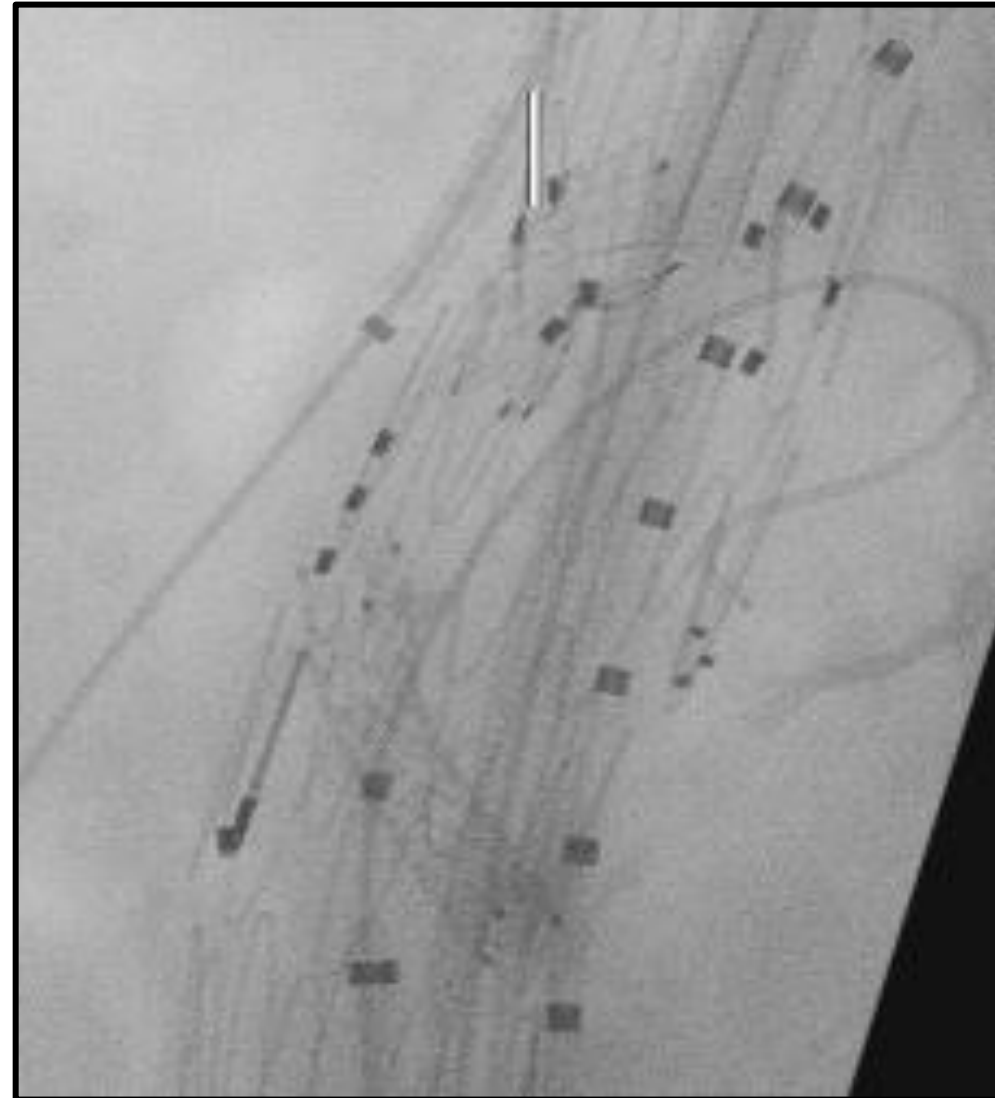iCover 5 x 27 mm







**16h00: LRA stil not catheterized**  
**And**  
**RRA is not anymore catheterized**



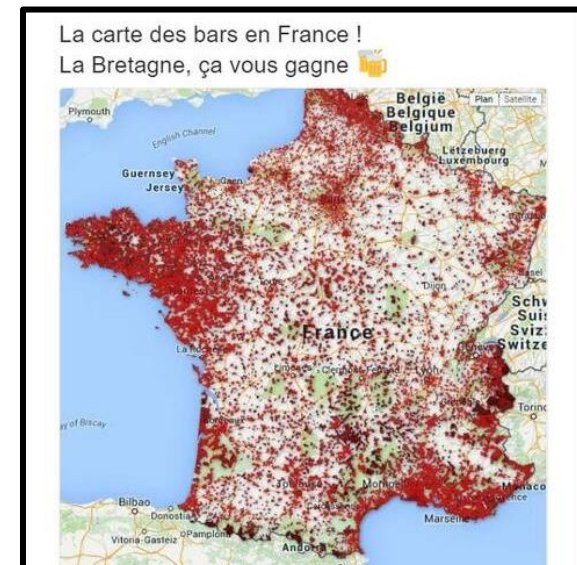
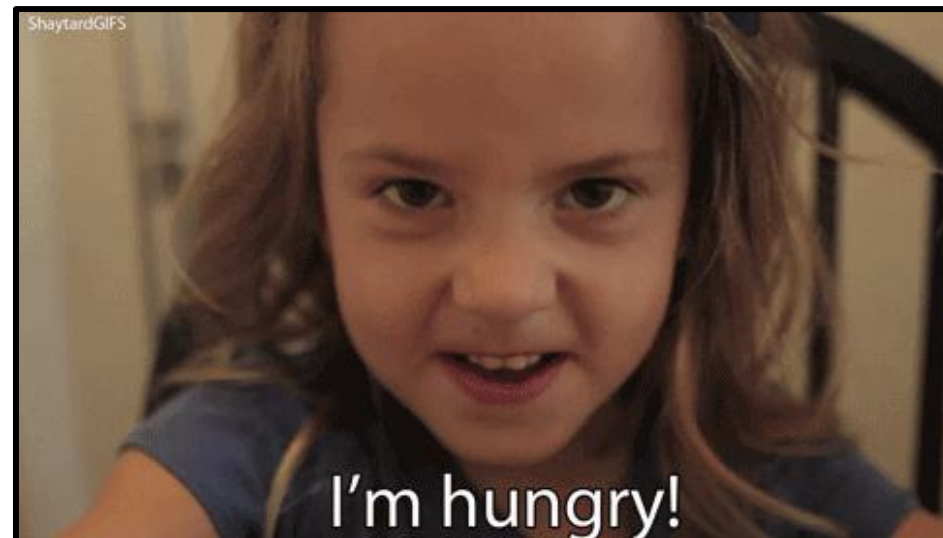
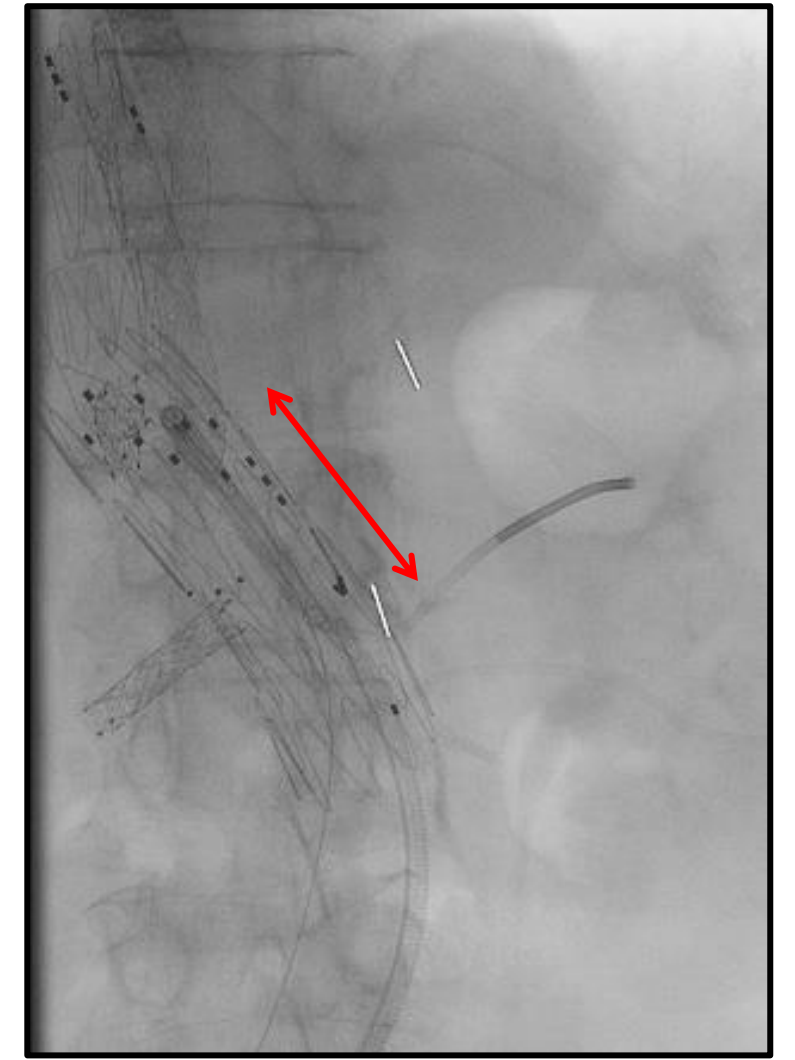


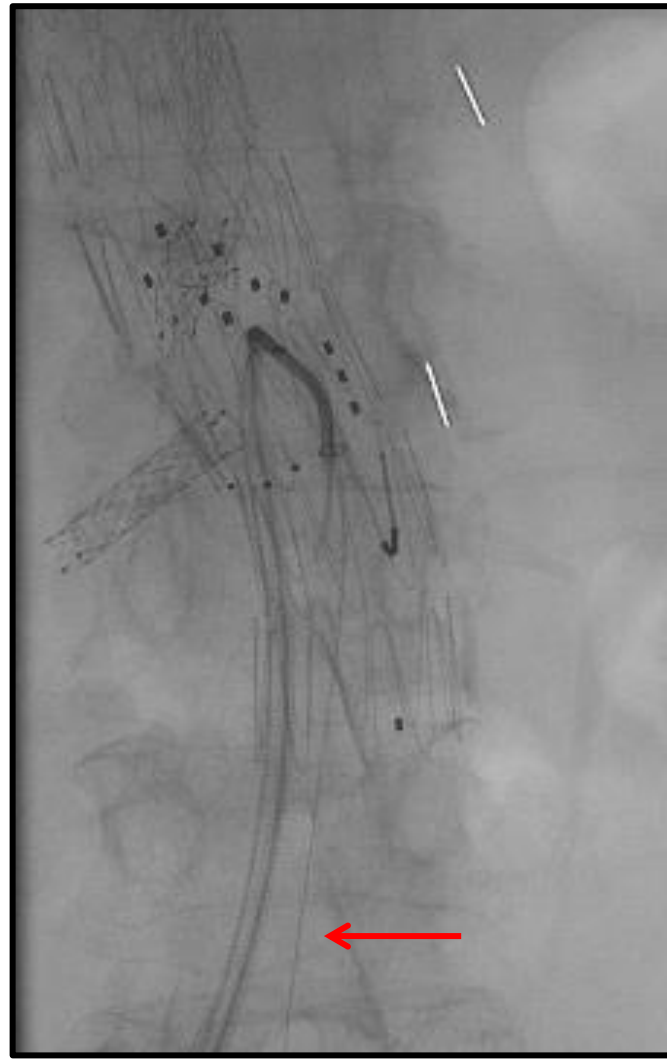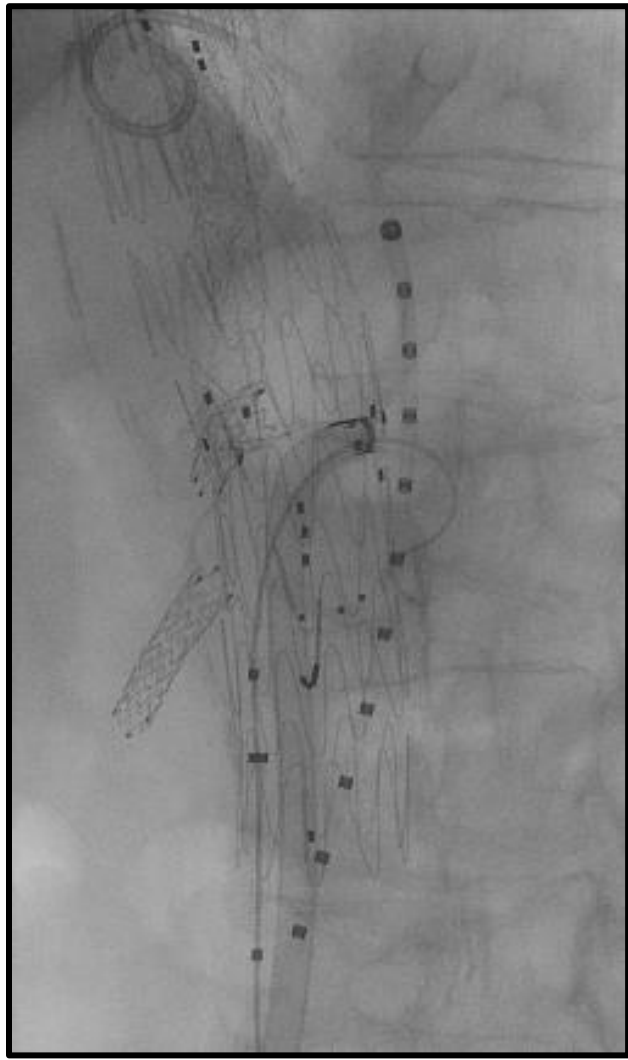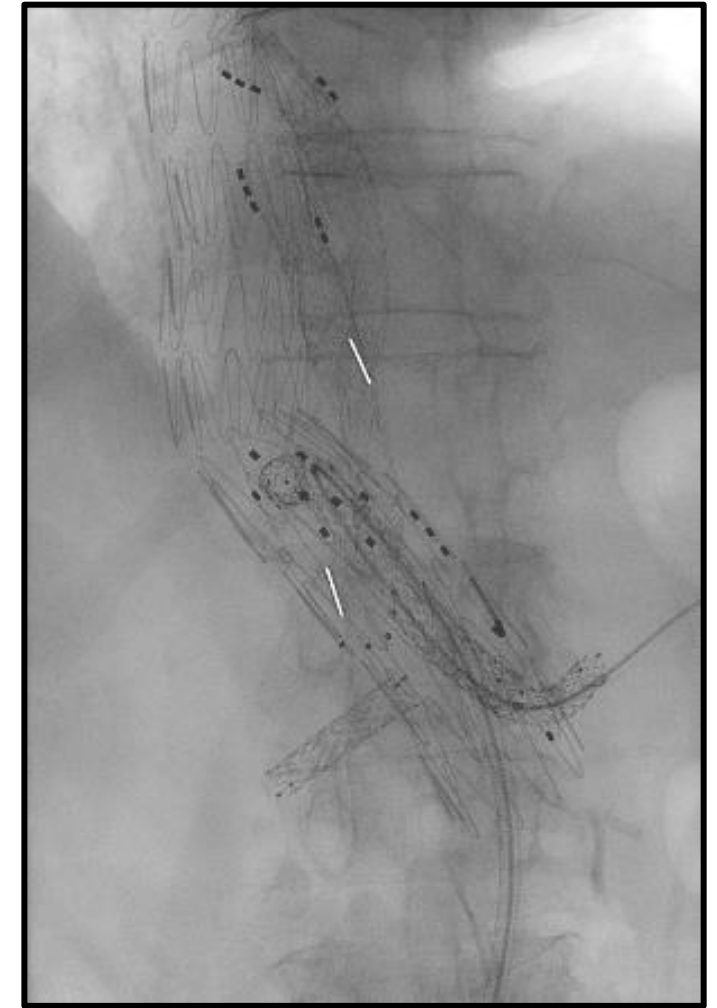
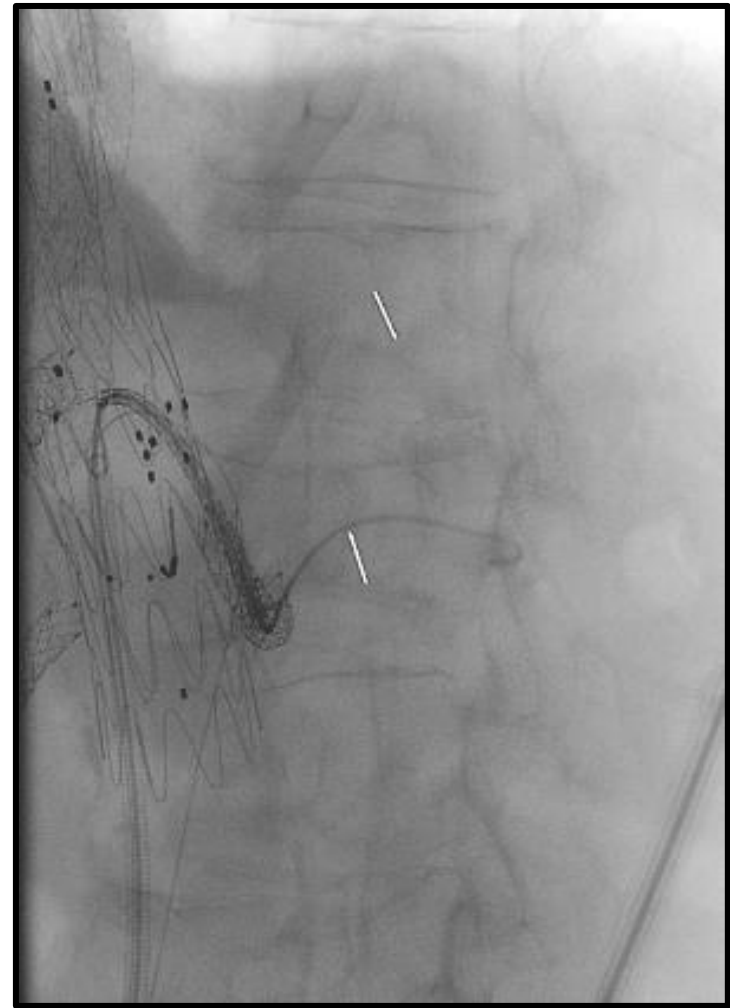
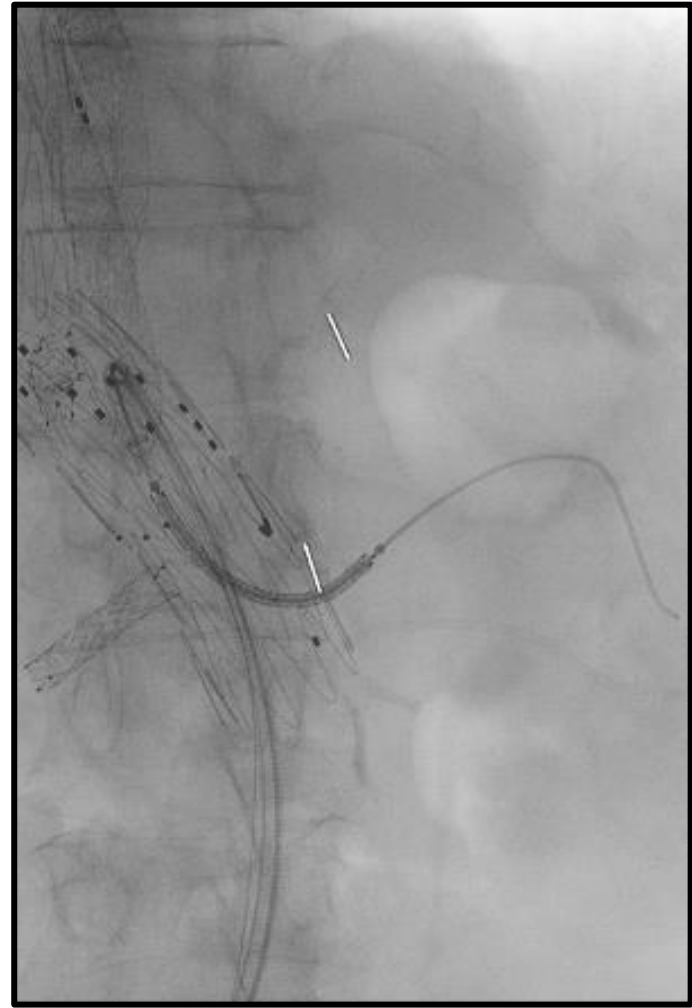## The Jockers



- Trying to catheterize one renal artery
- Perform the iliac bifurcated endograft in a second step

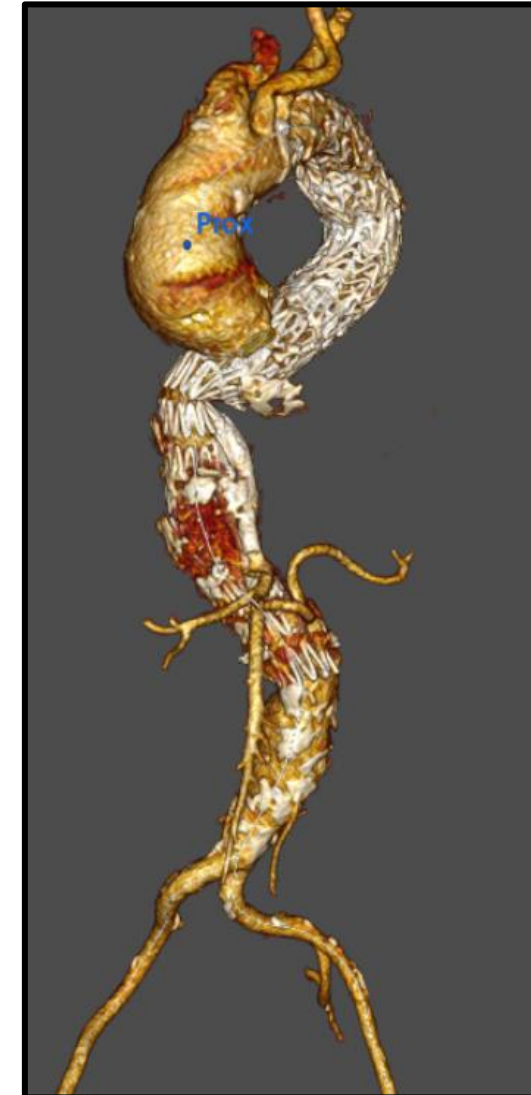
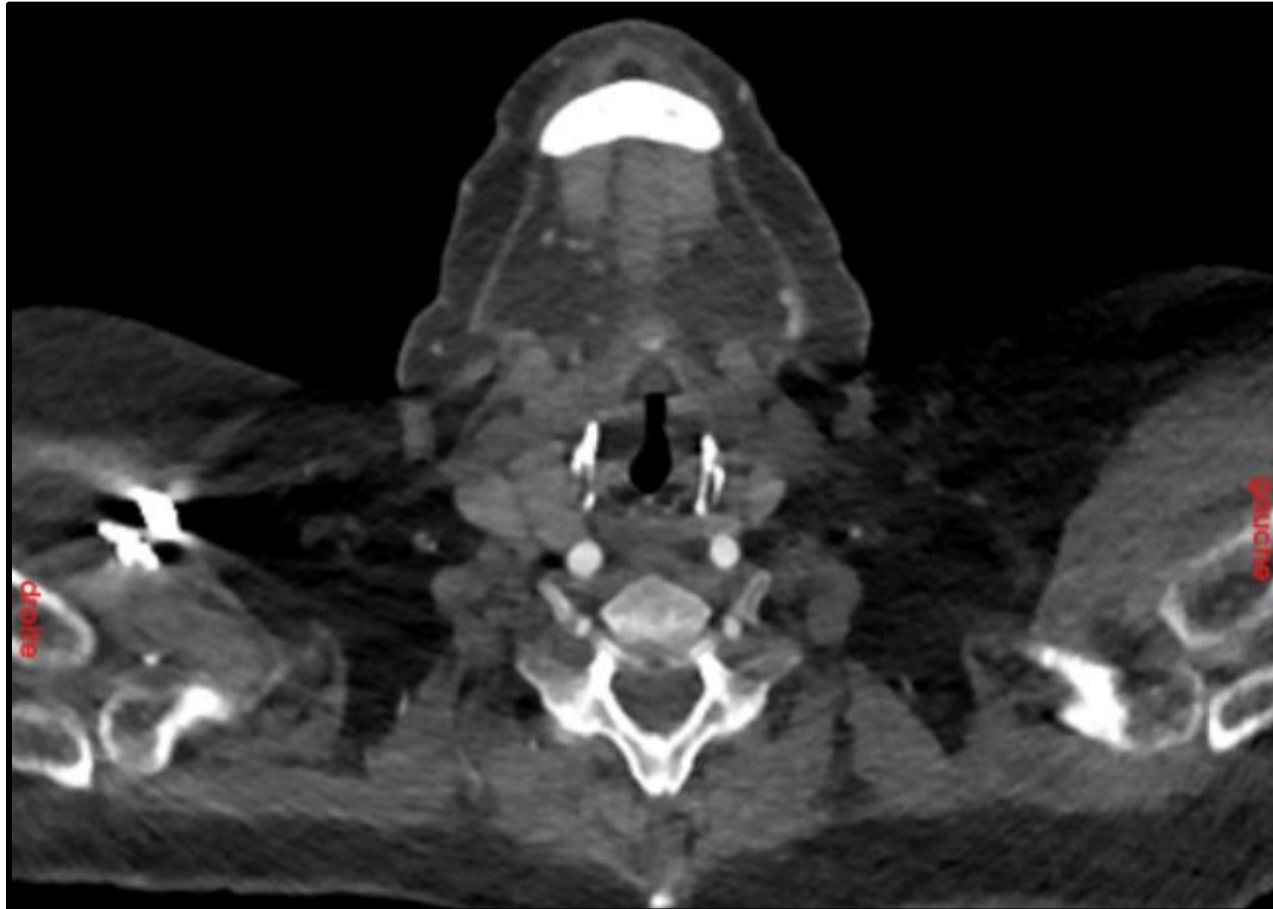










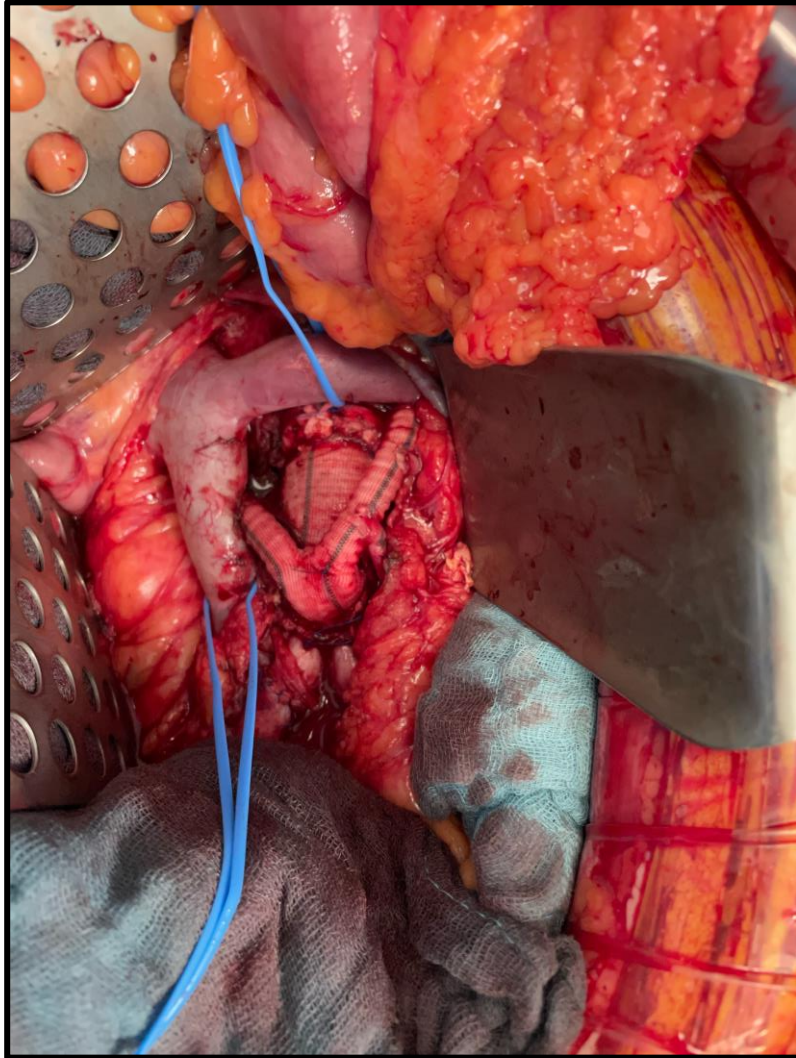
# Post operative CT-scan

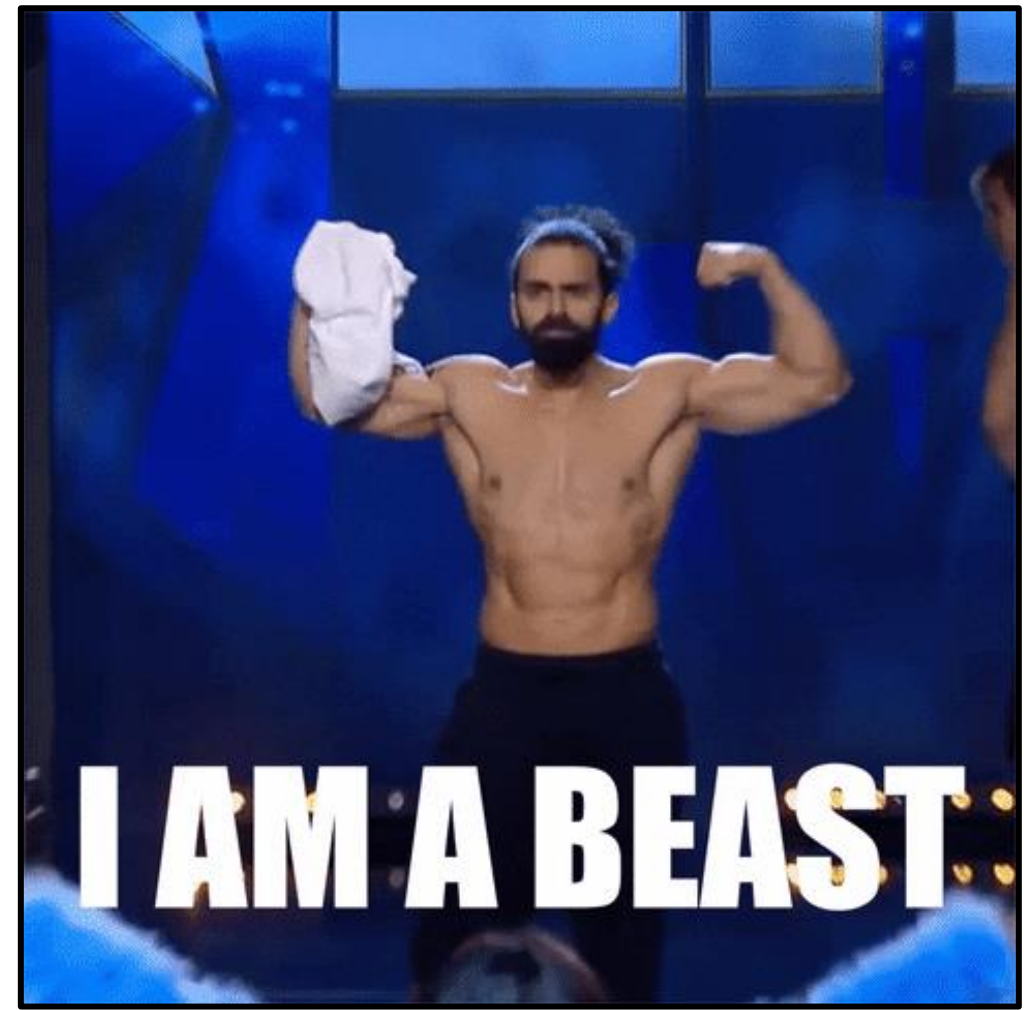

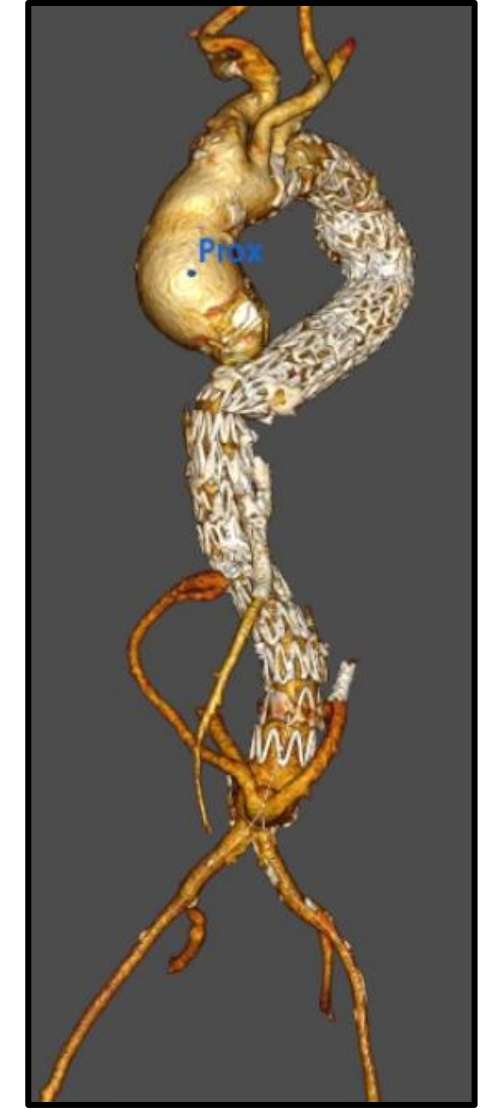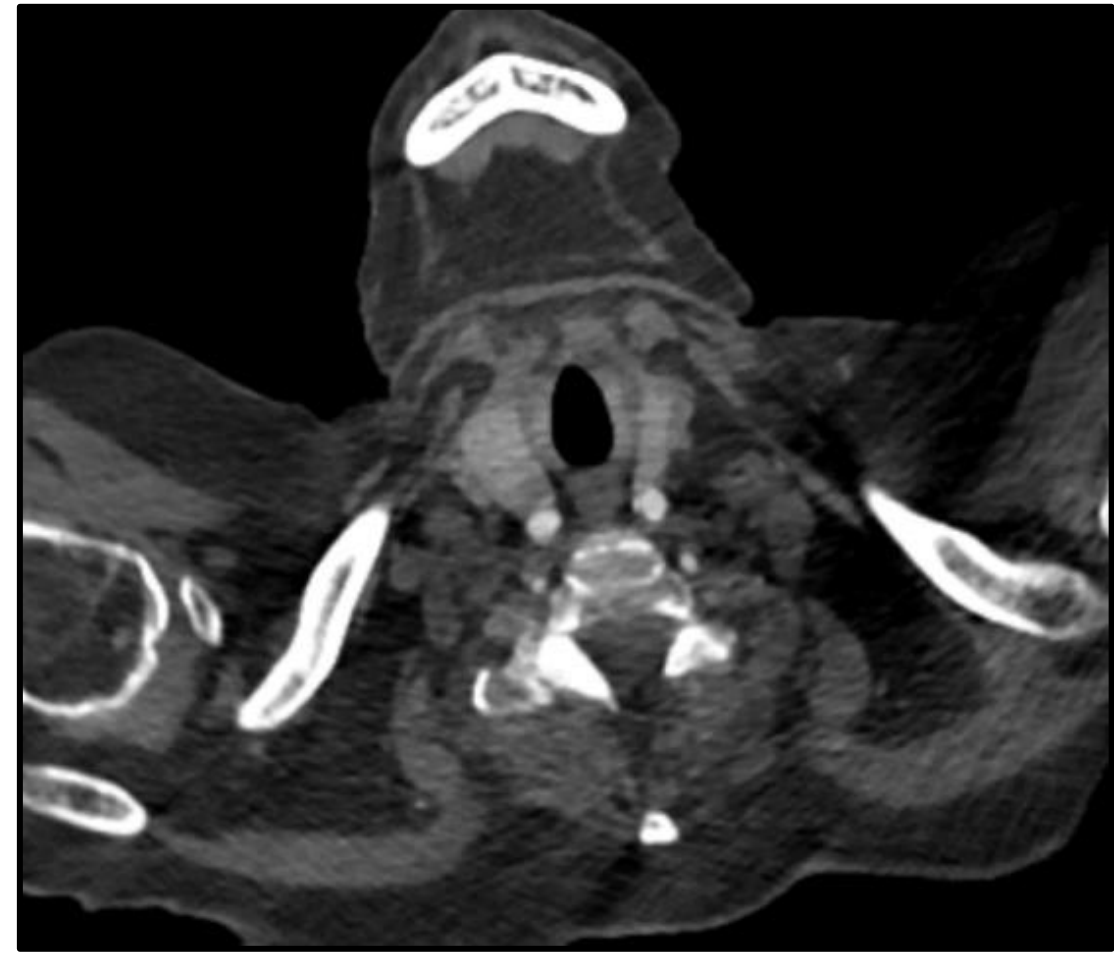
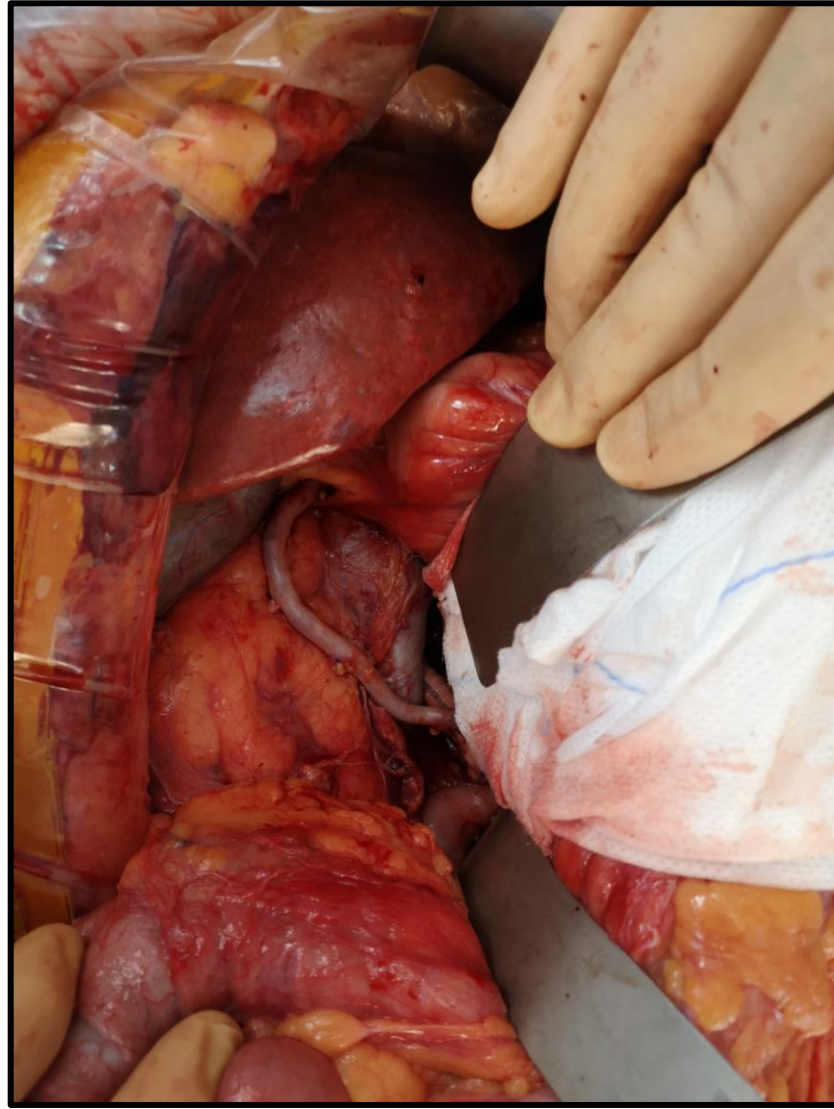


3 weeks after ...


Revenge is better than christmas











L'esprit scientifique se constitue sur un ensemble d'erreurs  
rectifiées

Gaston BACHELARD