



Dissection: « la vérité est ailleurs »



Mme L

- 55 y/o female
- No cardiovascular comorbidity
- Hypertension
- Smoking
- Sudden thoracic and abdominal pain
 - Normal first clinical assessment : left at home
 - New onset : emergency unit
- Biological tests
 - Troponin I 229
- ECG: anteroseptal ST+
- Coronarography : no major lesion

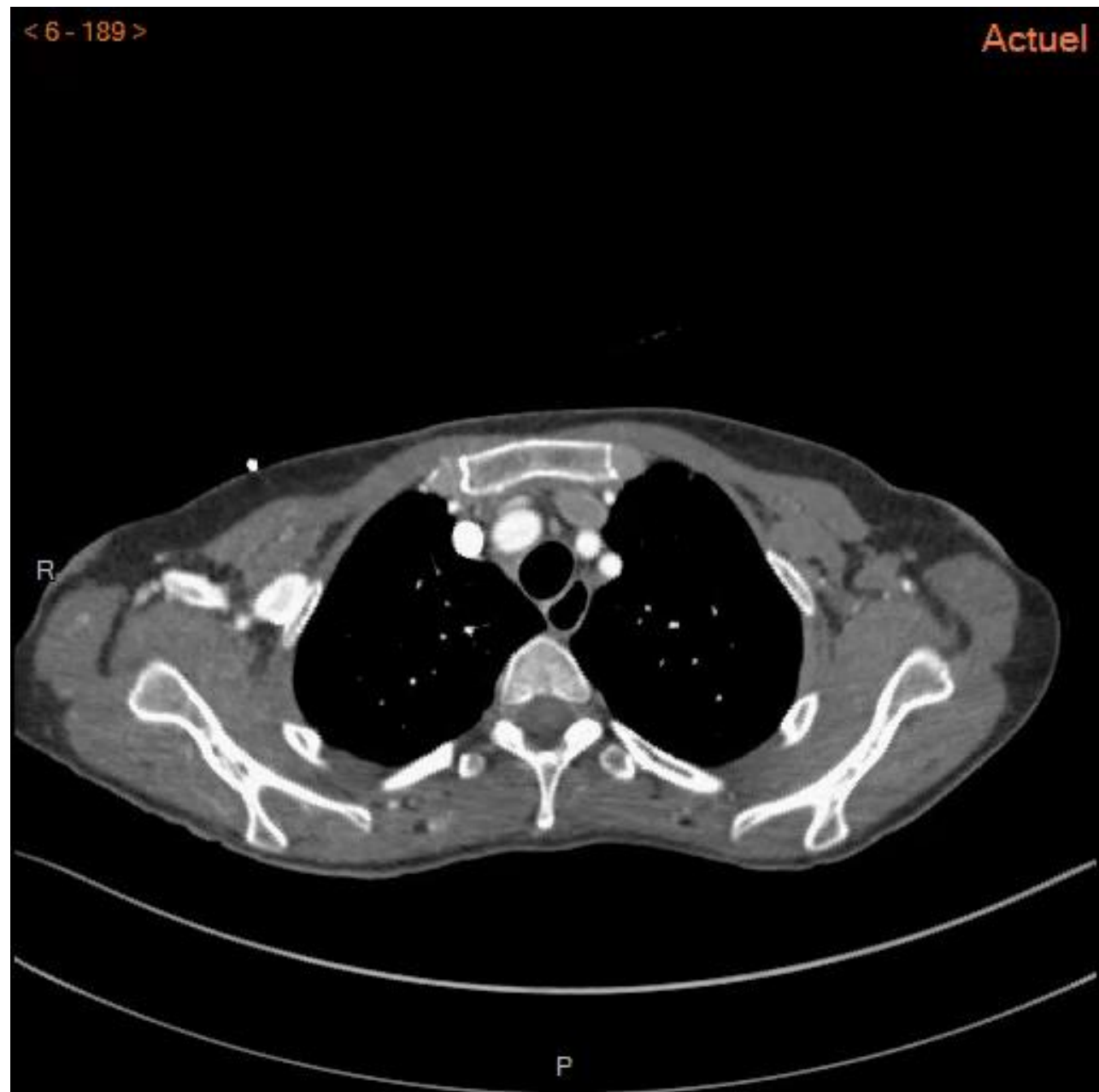Mme L

- ICU hospitalization
- Acute kidney injury with anuria
- Permanent pain
 - lumbar
- Loss of pulseness and sensitivity right inferior limb first then both
- Abdominal DUS
 - No ureteral nor vesical obstruction
 - Aortic dissection
- Biological tests
 - pH=7.24, lactate=5.1, creatinin=330, ASAT=348, ALAT=371
- CT scan

TDM preOP

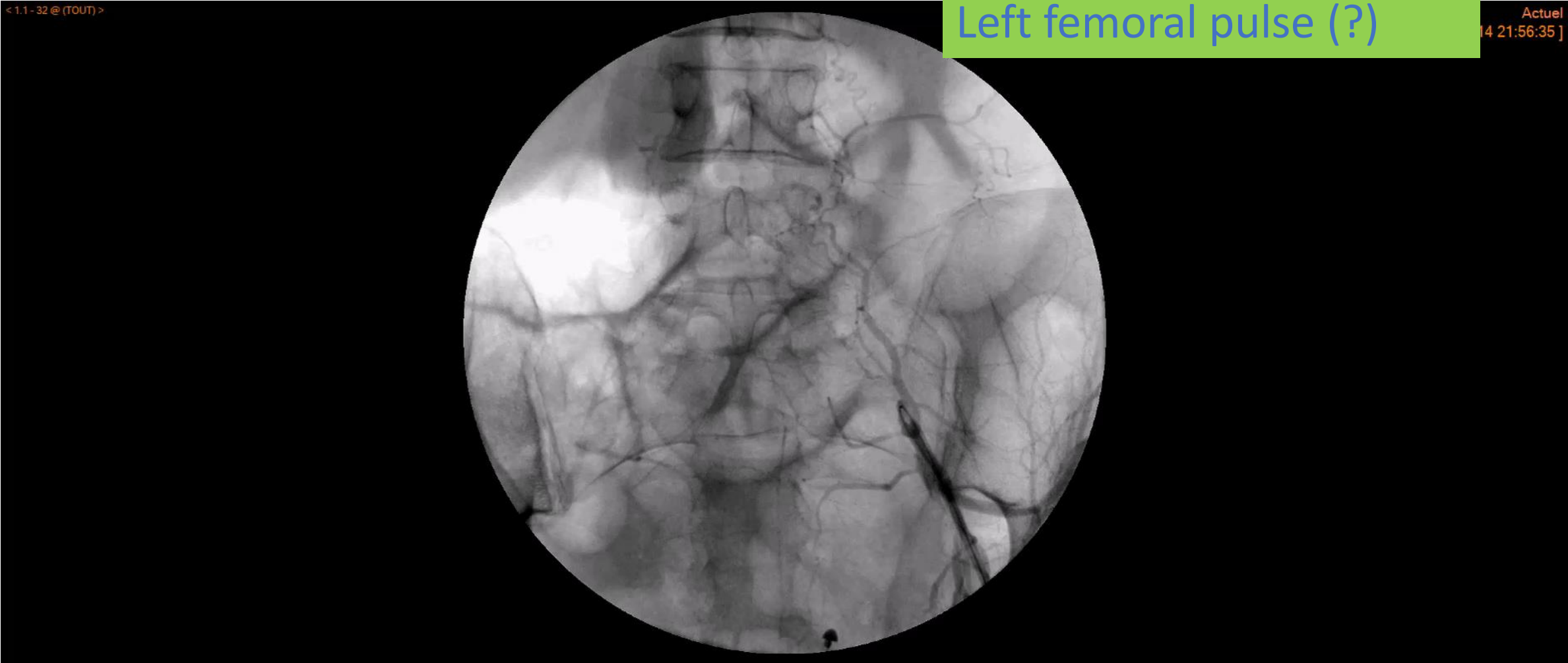
Mme L

- Type B dissection
- Bilateral renal infarctus
- Dynamic (?) coeliac trunk obliteration
- SMA patency
- Static (?) aortic obliteration
- Bowel dilation

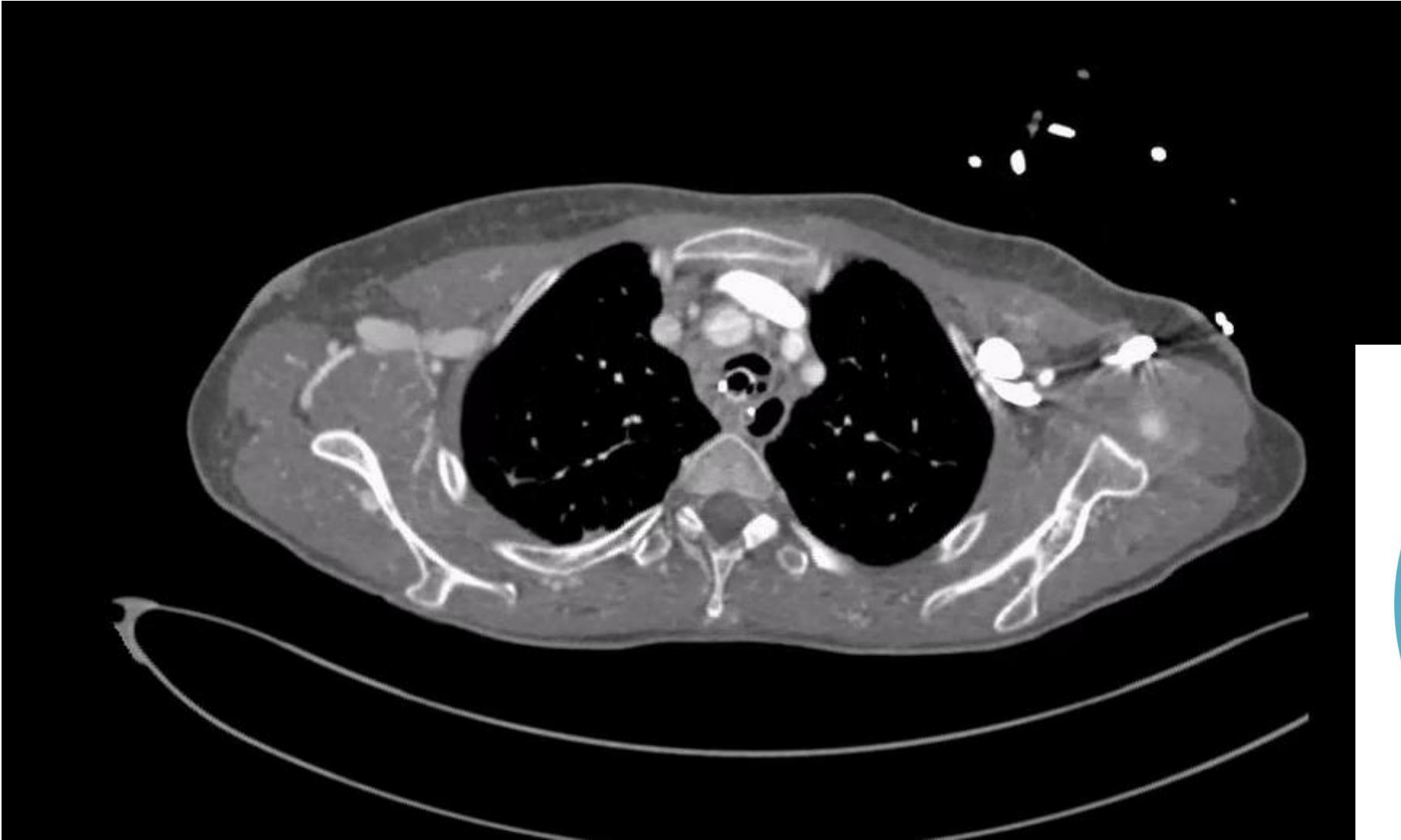

Procedure

Right femoral pulse +
Left femoral pulse (?)



TDM postop



Second procedure

- Laparotomy
- Supraceliac control
 - Pulse +
 - clamping
- Aortotomy
 - Renal level
 - Aortic disease
 - Old thrombus removal
 - Intraluminal flap resection until proximal clamping
- Aortobifemoral bypass
- SMA reimplantation
 - Small bowel revascularization +
 - Hepatic pulse +
- Omentoplasty, cholecystectomy, laparostomy



Postoperative curse

- pH 6.9
- Hemodynamic instability after declamping
- Hypothermia
- Hemorrhagic shock
- Death

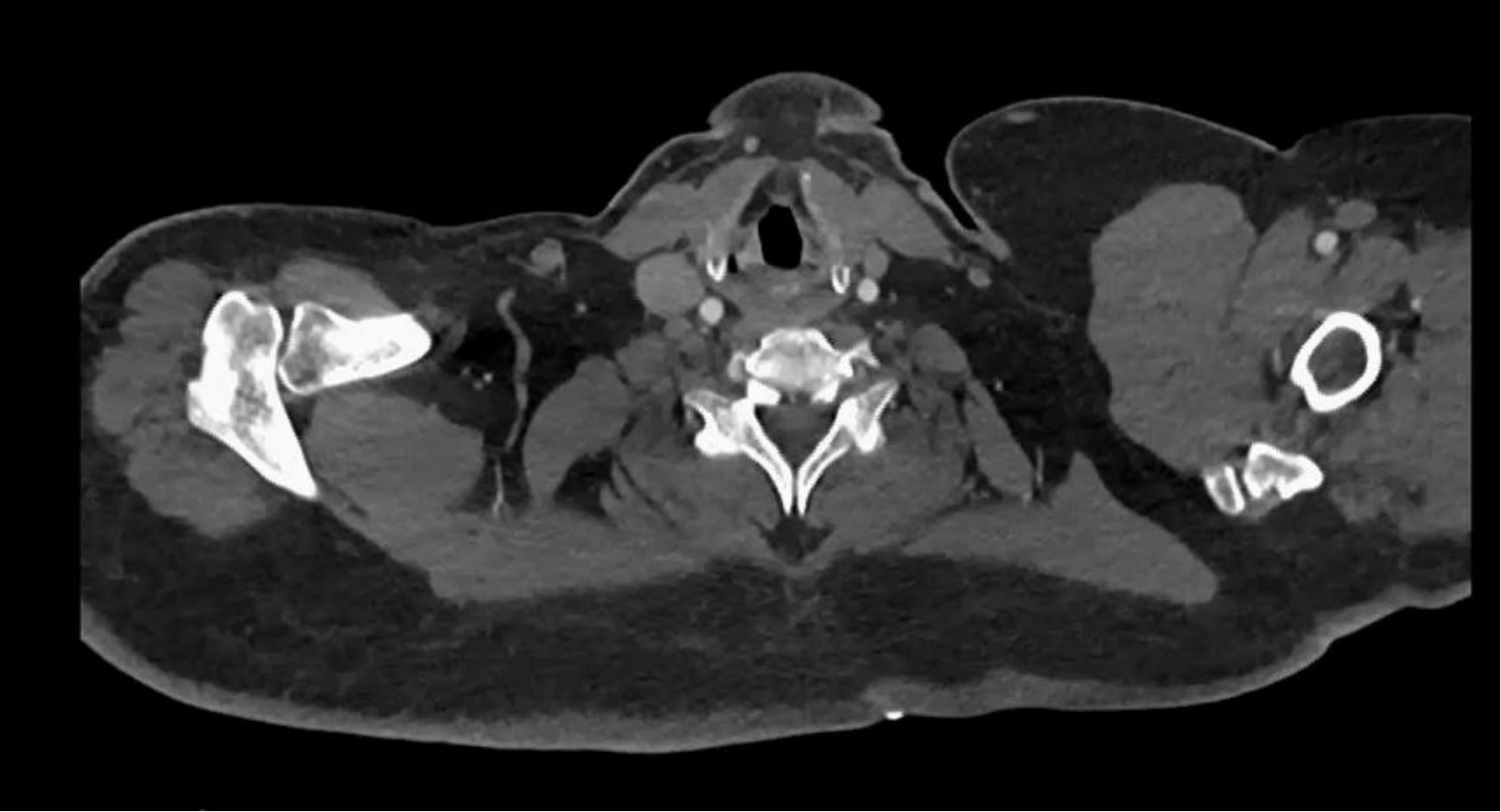


Mr G

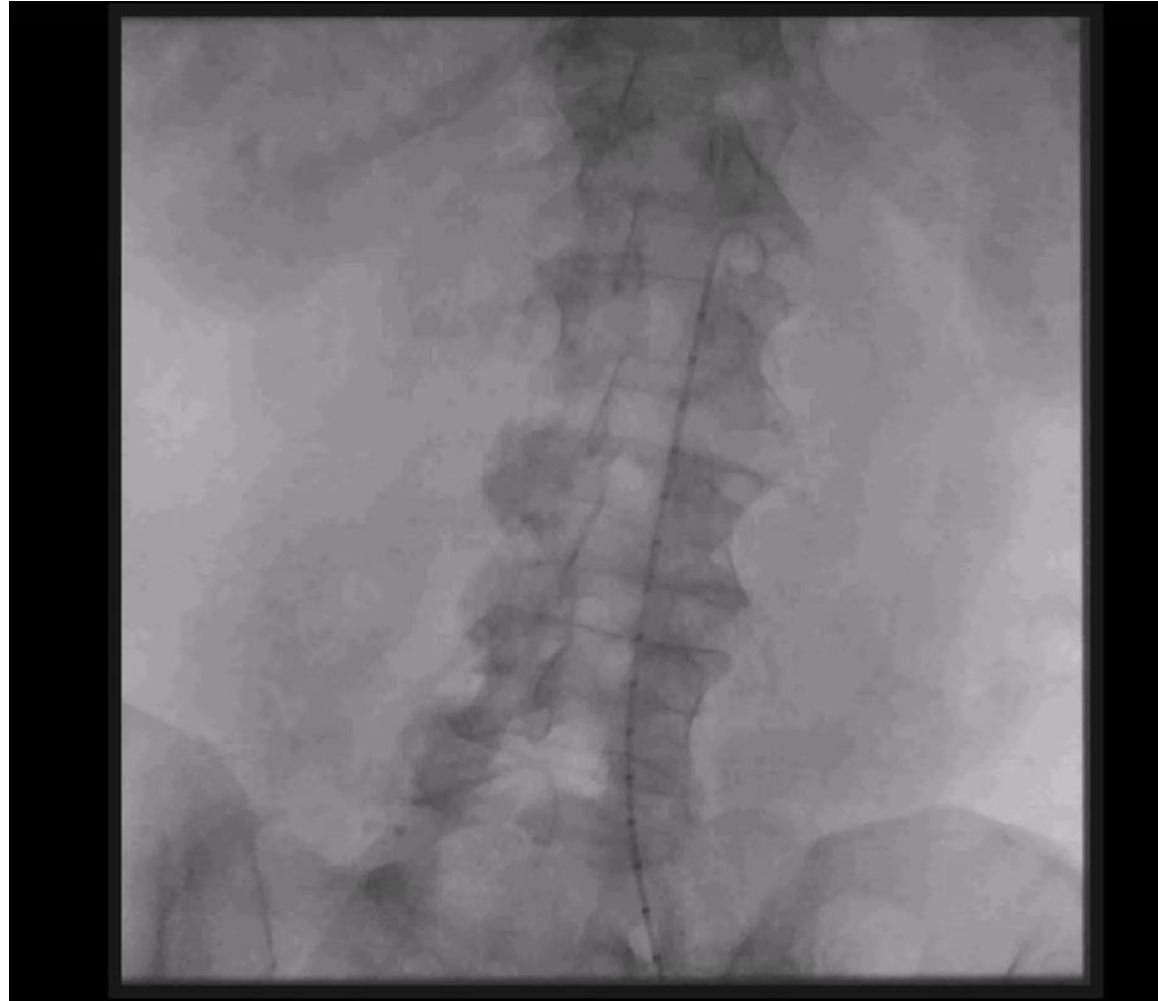- 65 y/o male
- No cardiovascular comorbidity
- Not treated hypertension
- Obesity ++
- Beginning dementia
- Sudden right limb pain
- Right femoral pulse abolished
- Right limb loss of sensitivity and motricity
- Left femoral +

TDM preOP

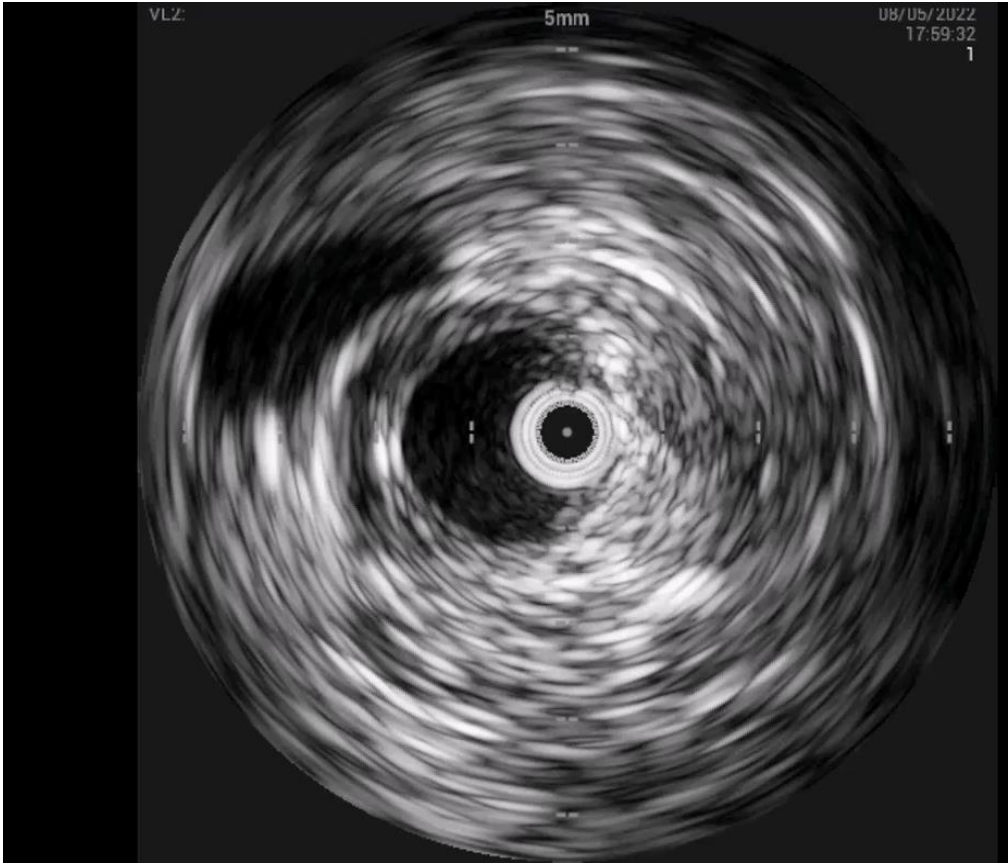
Mr G



Procédure

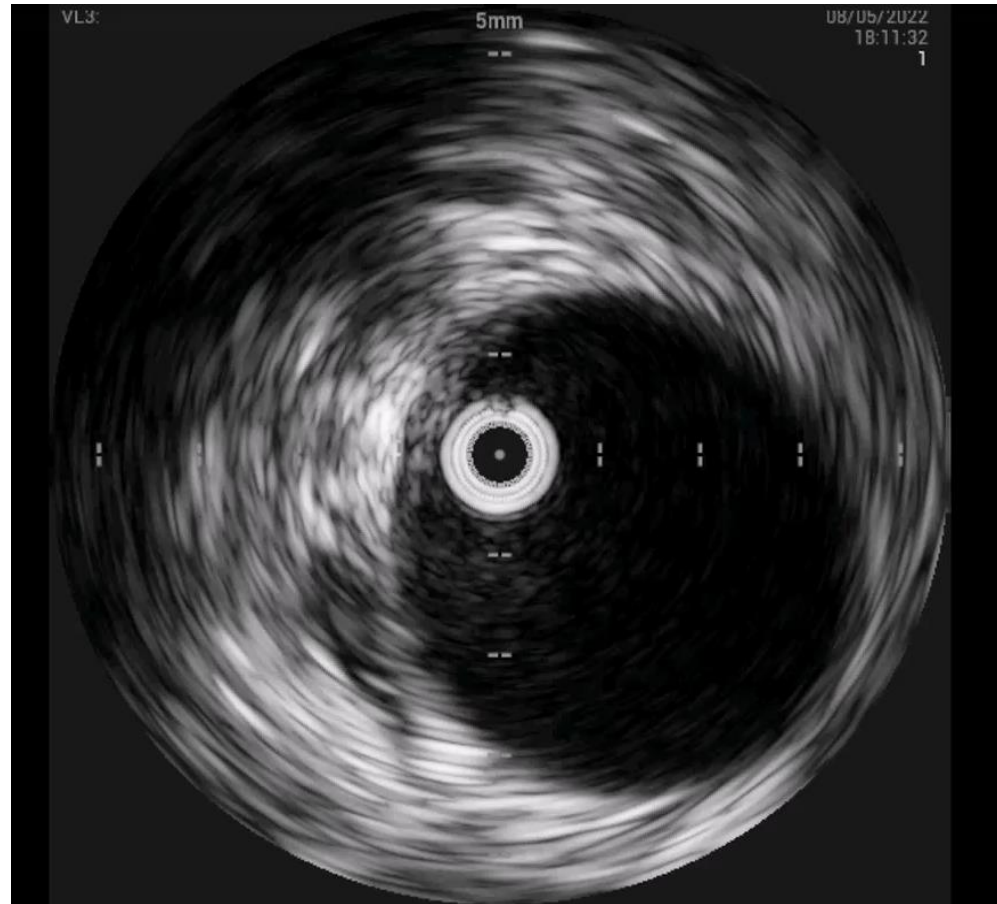


IVUS assessment



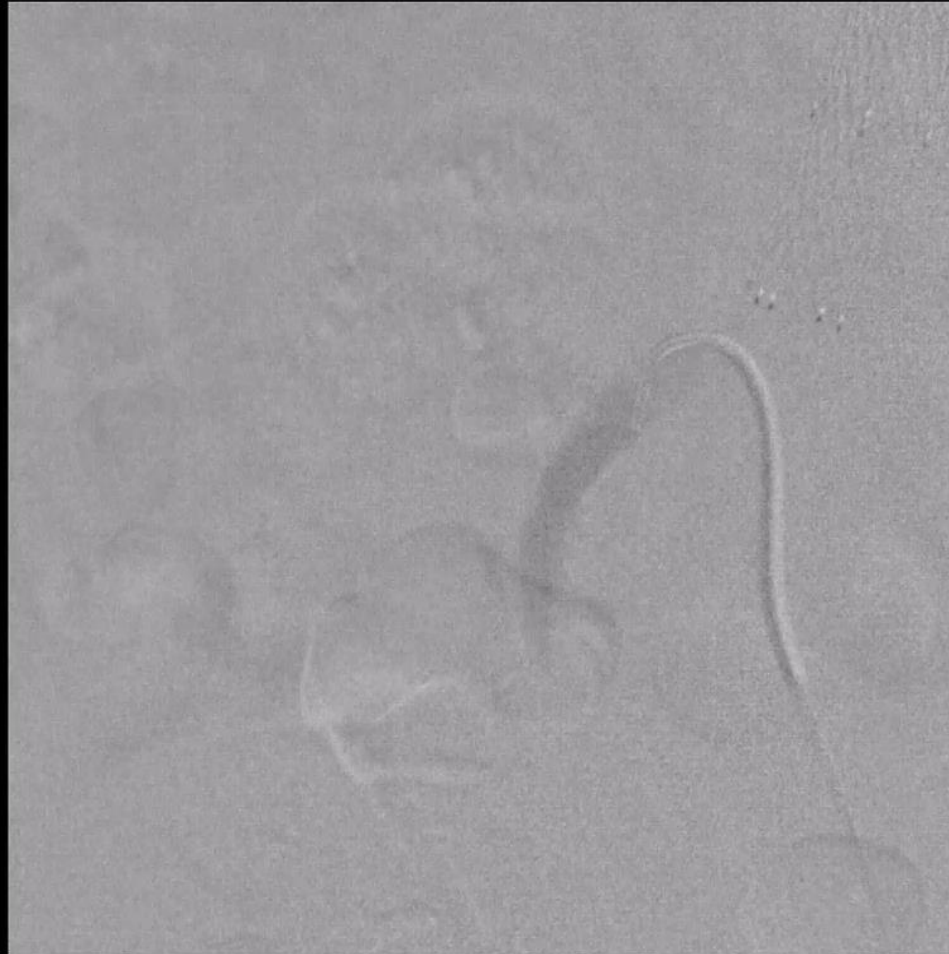Aortic stent

2 SINUS XL Stents



Procédure


< 5.1 - 18 @ (TOUT) >



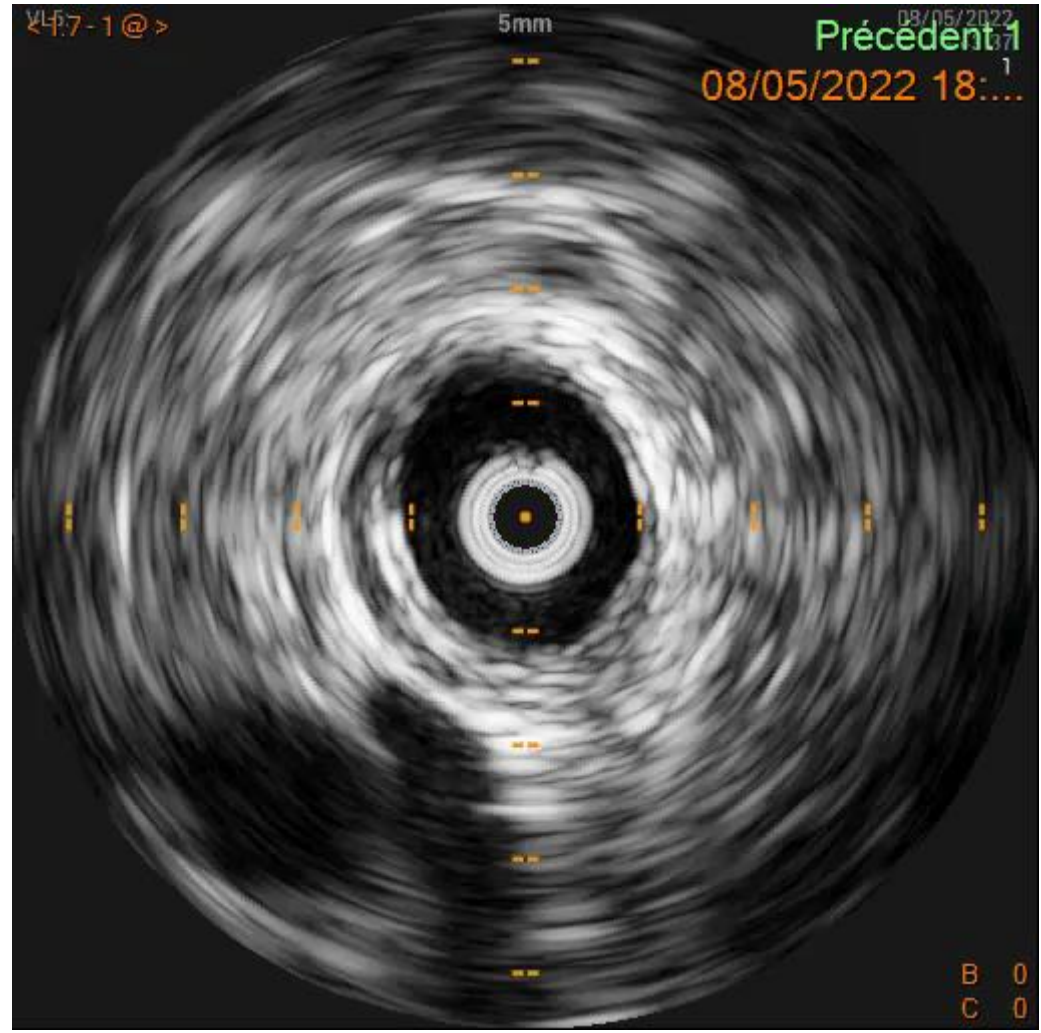
Actuel
[08/05/2022 19:14:19]

Procédure

<9.1-7 @ (TOUT) >




Actuel
[08/05/2022 19:28:24]

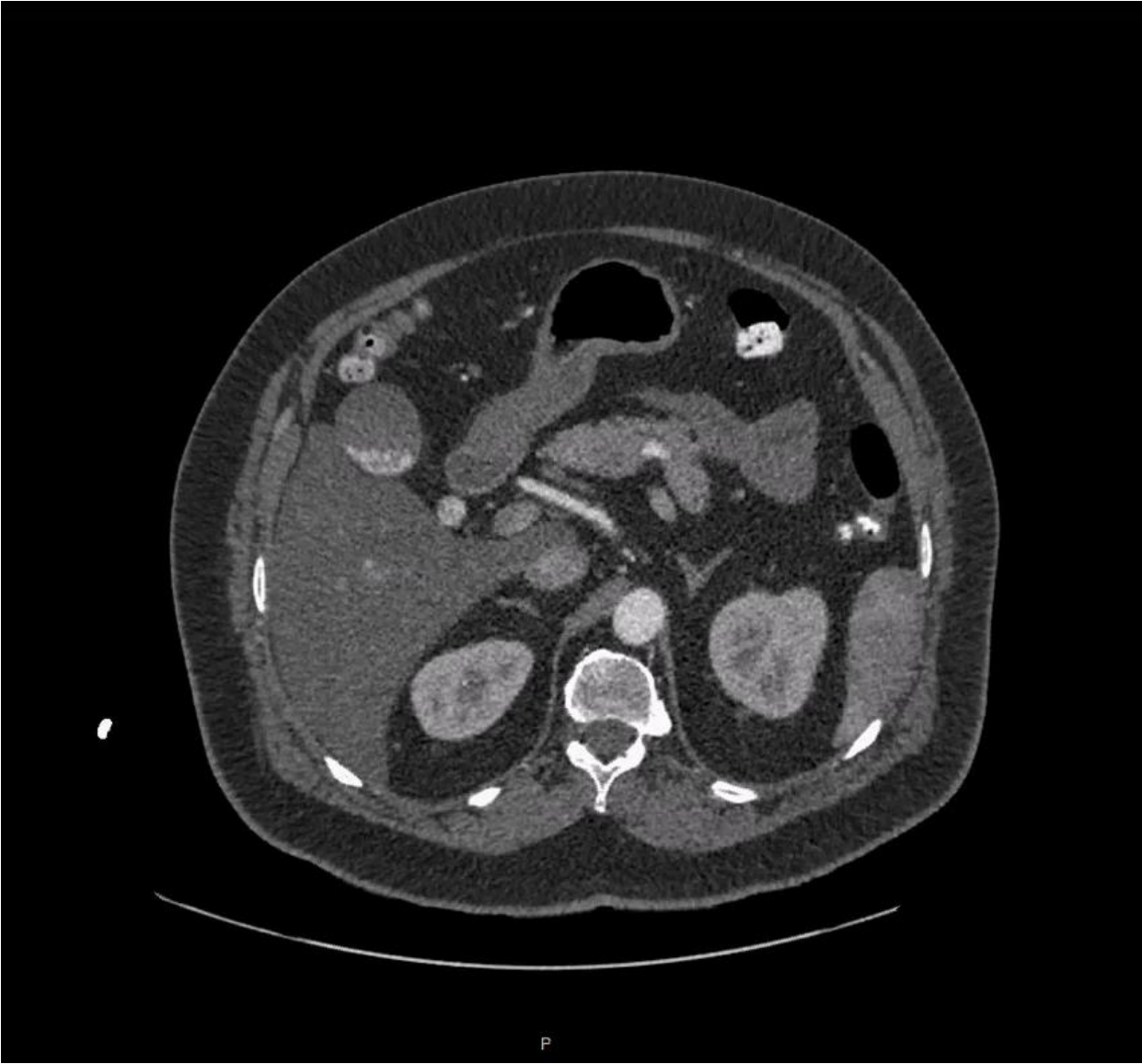

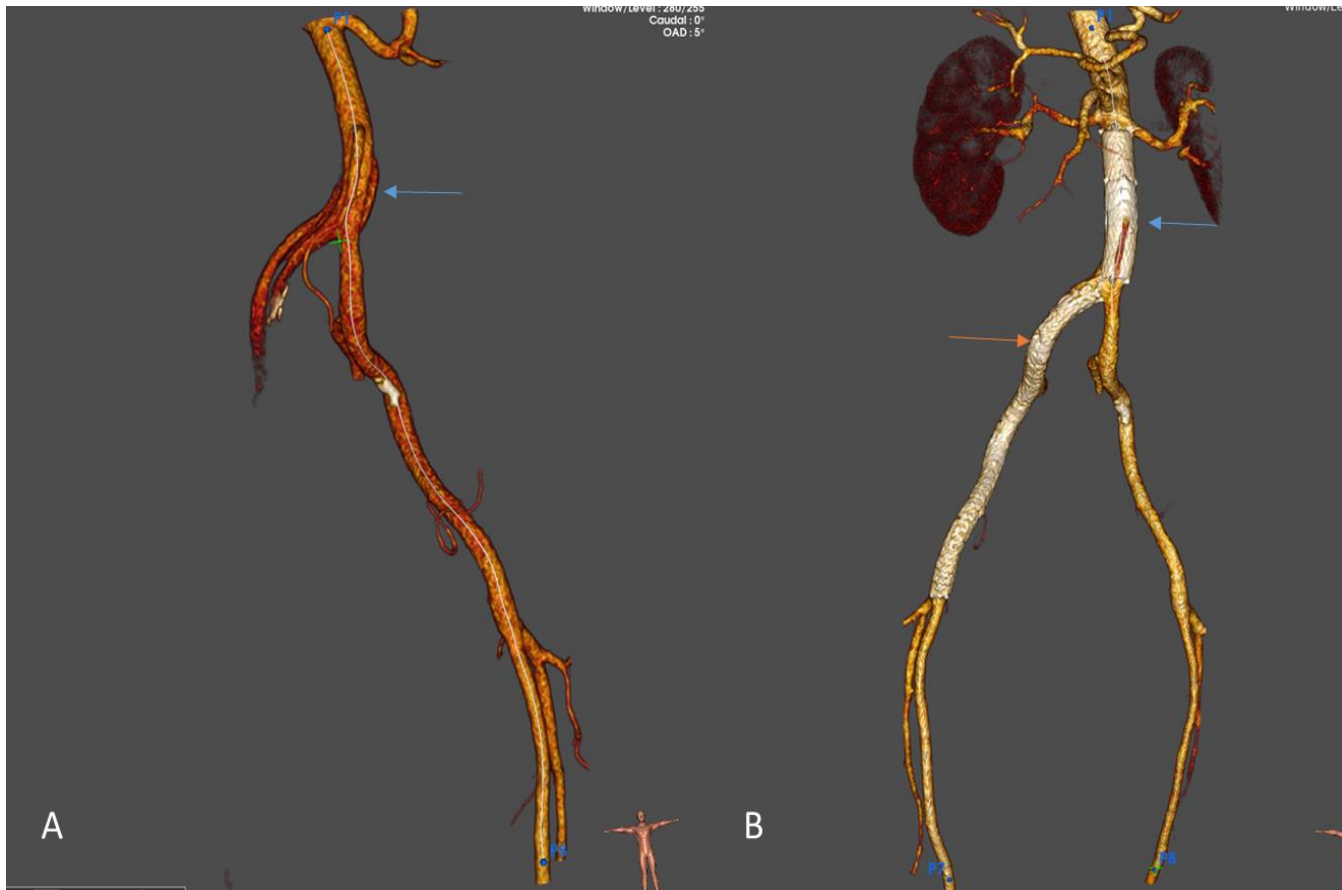< 15.1 - 8 @ (TOUT) >

Actuel
[08/05/2022 19:57:32]



TDM post





13:09 74%

Reception



Pour seulement 9,45€ offrez-vous une pépite issue de l'iconique vignoble des Graves. 🏆 Médaillé d'Or, Château Ducasse 2018 vous séduira par sa bouche charmeuse et gorgée de fruits.

🔄 ✓ 🗑️ ⬅️ ⋮

☰ ○ <

