



25th European Vascular Course

Challenging Case

Alexandros Mallios, M.D.

Director of Vascular Access

GH Paris St Joseph

& Chief of Vascular Surgery

CH Chartres

France

Disclosures:

Speaker name: **Alexandros Mallios, MD**

I have the following potential conflicts of interest to report:

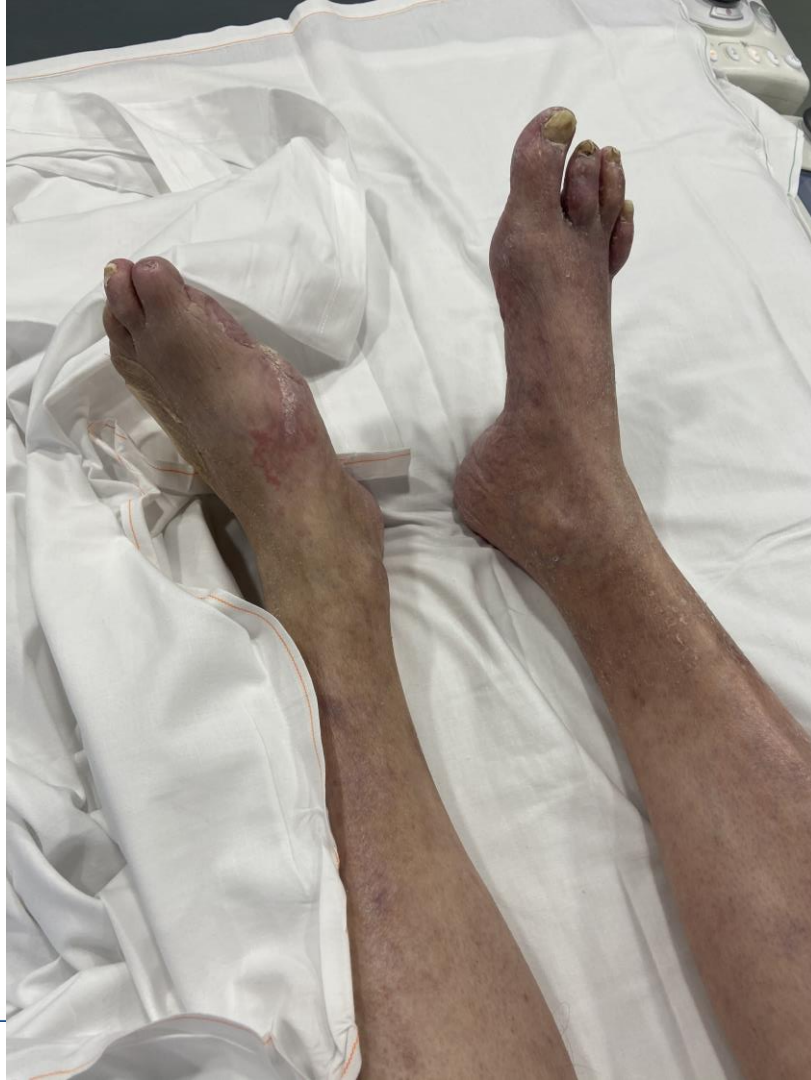Participation in a company-sponsored speaker bureau, shareholder, consultant

–

– Avenue Medical, Medtronic, Laminate Medical, Sonosite, Contego Medical, Boston Scientificm, Medistim

59 year old patient

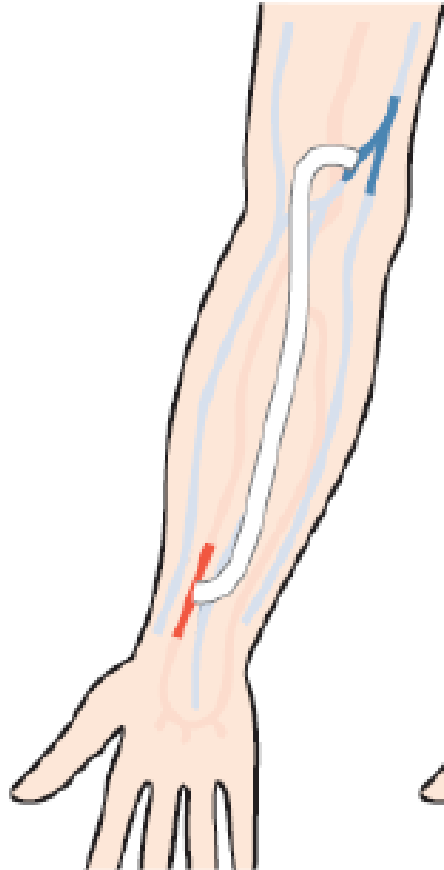
- Severe Arterial Disease, Diabetes
- Dialysis on Femoral Catheter
- Multiple previous bilateral AVF failed, ligated for Ischemia
- Notion of Central Vein Occlusions
- Previous toe amputations



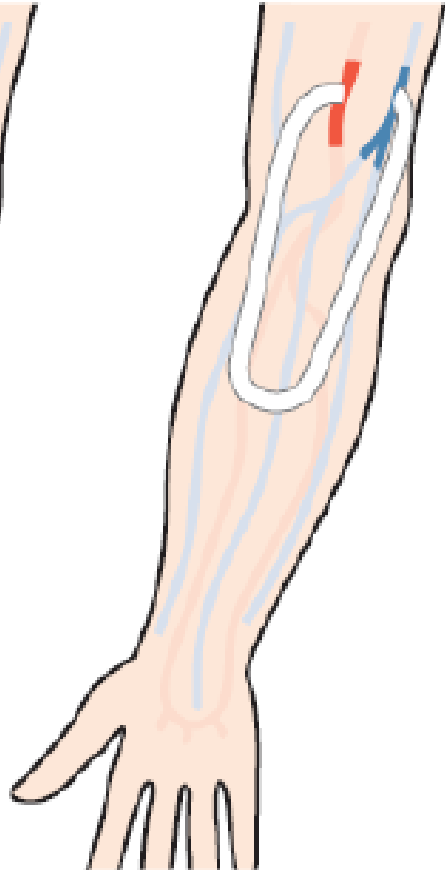
Request for Evaluation for new Upper Extremity Access – Options:

- Femoral graft
- Surfacar to change to jugular catheter
- Attempt Upper extremity relatively low Flow access
- Pretend that you don't understand send the patient back and change your phone number

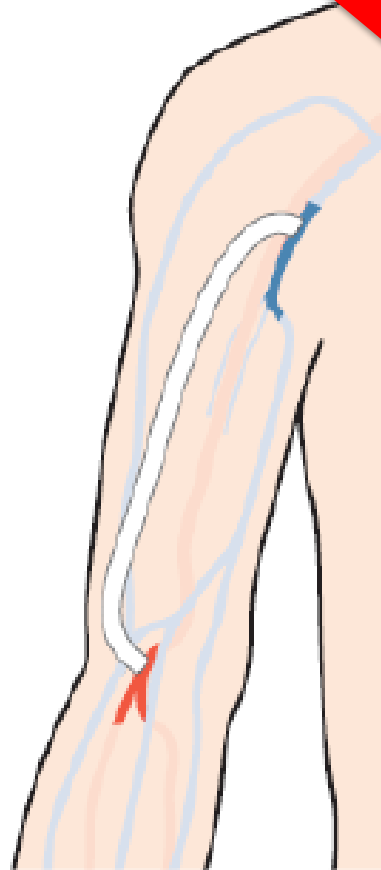
A



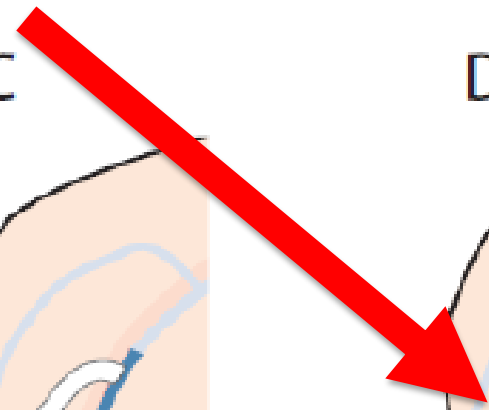
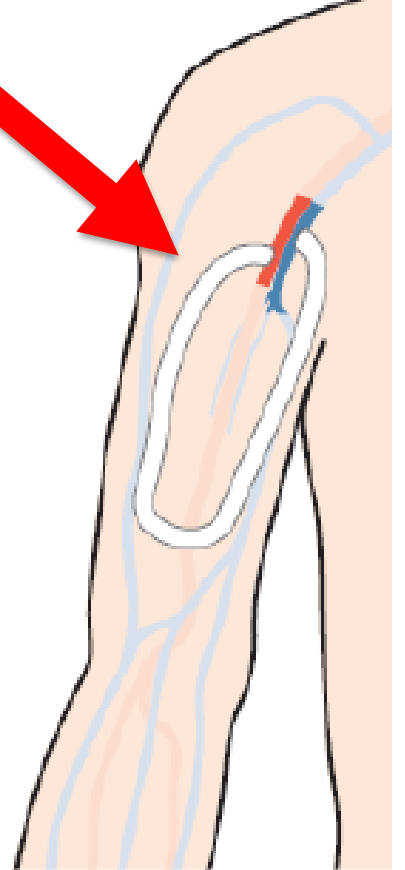
B



C

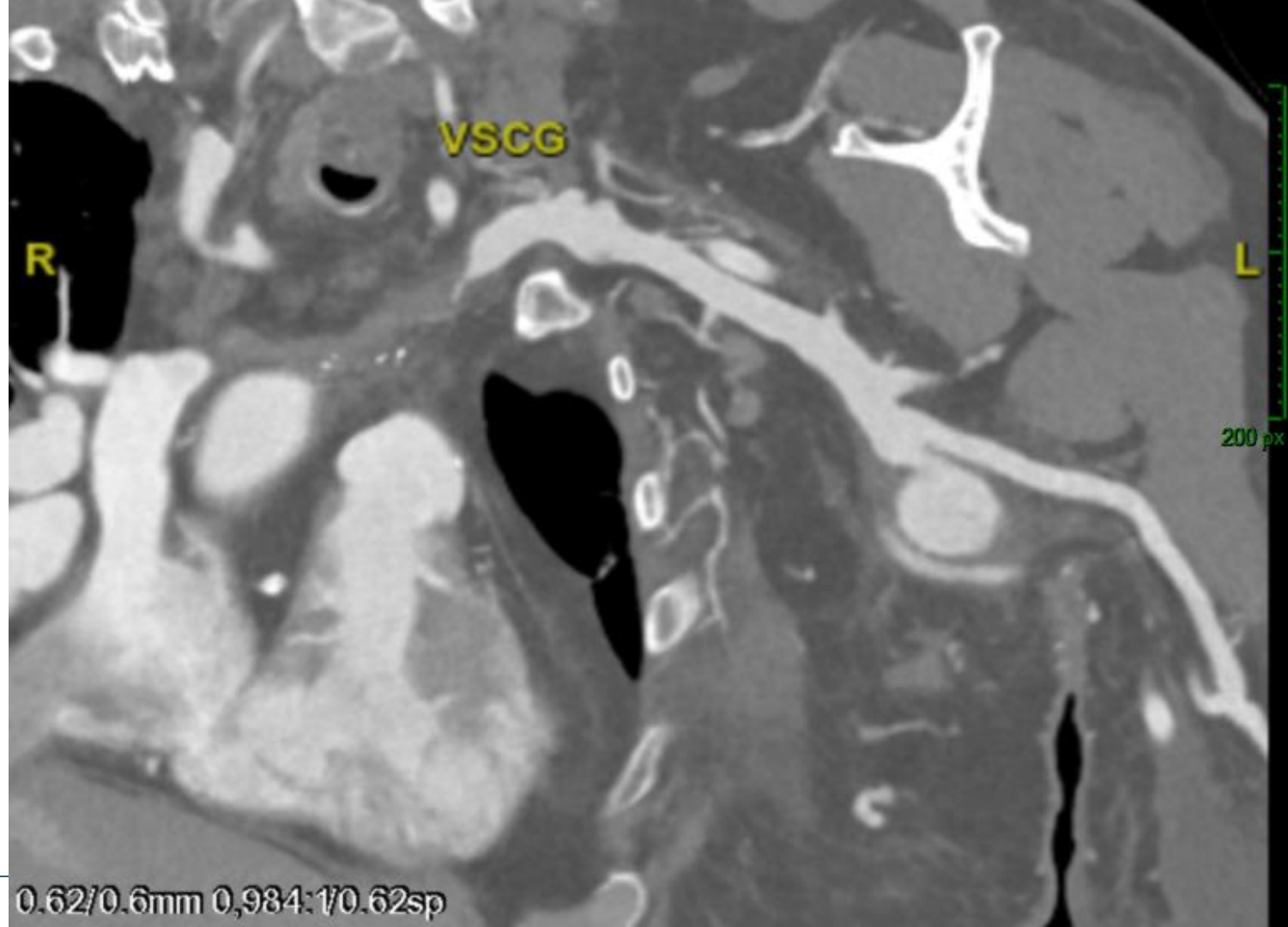


D



Successful Loop Graft

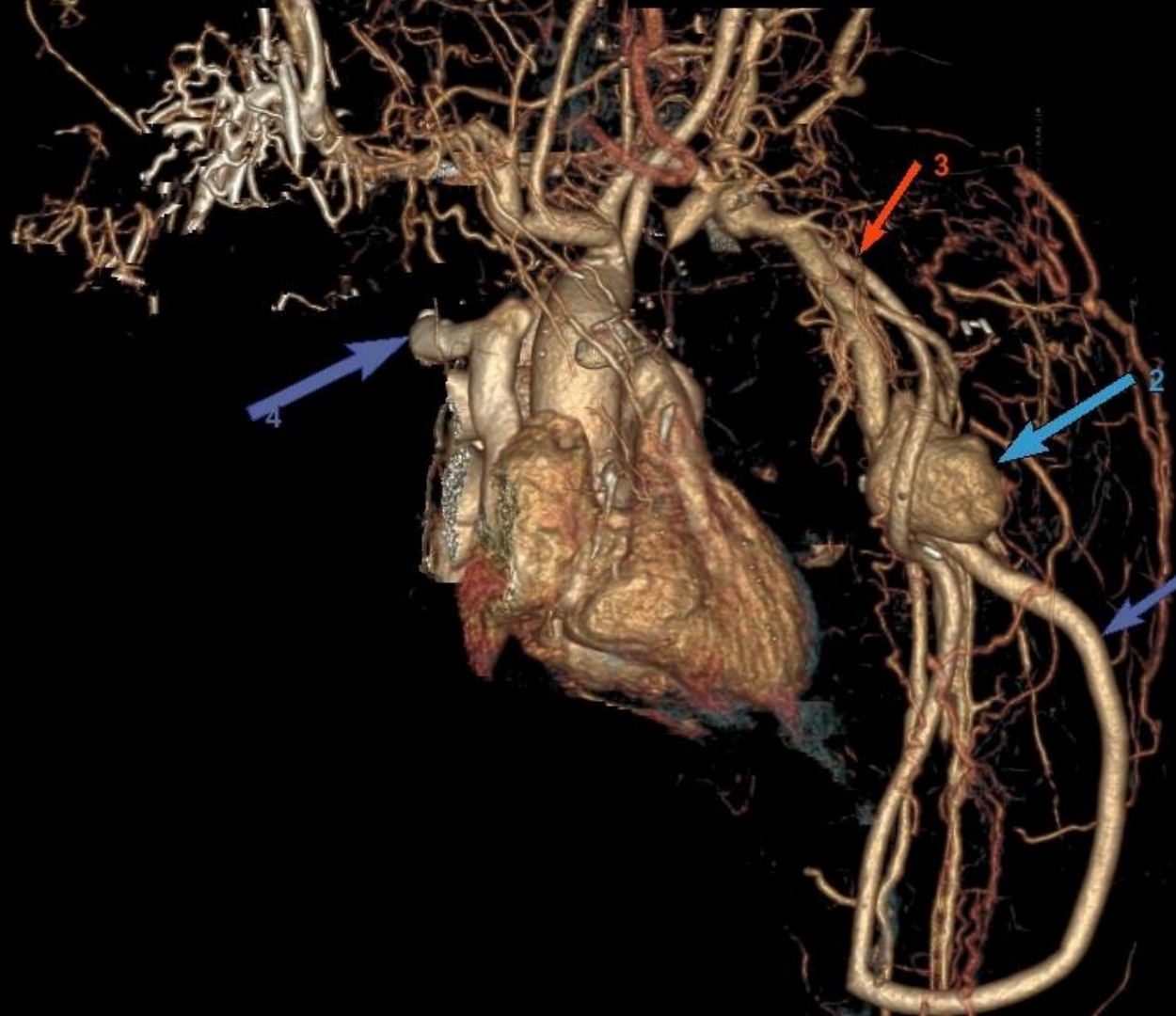
- Patient Dialysed for 3-4 months without problems
- Femoral Catheter Removed
- Phone call for swollen arm, possible SVC syndrome, no other access available for dialysis

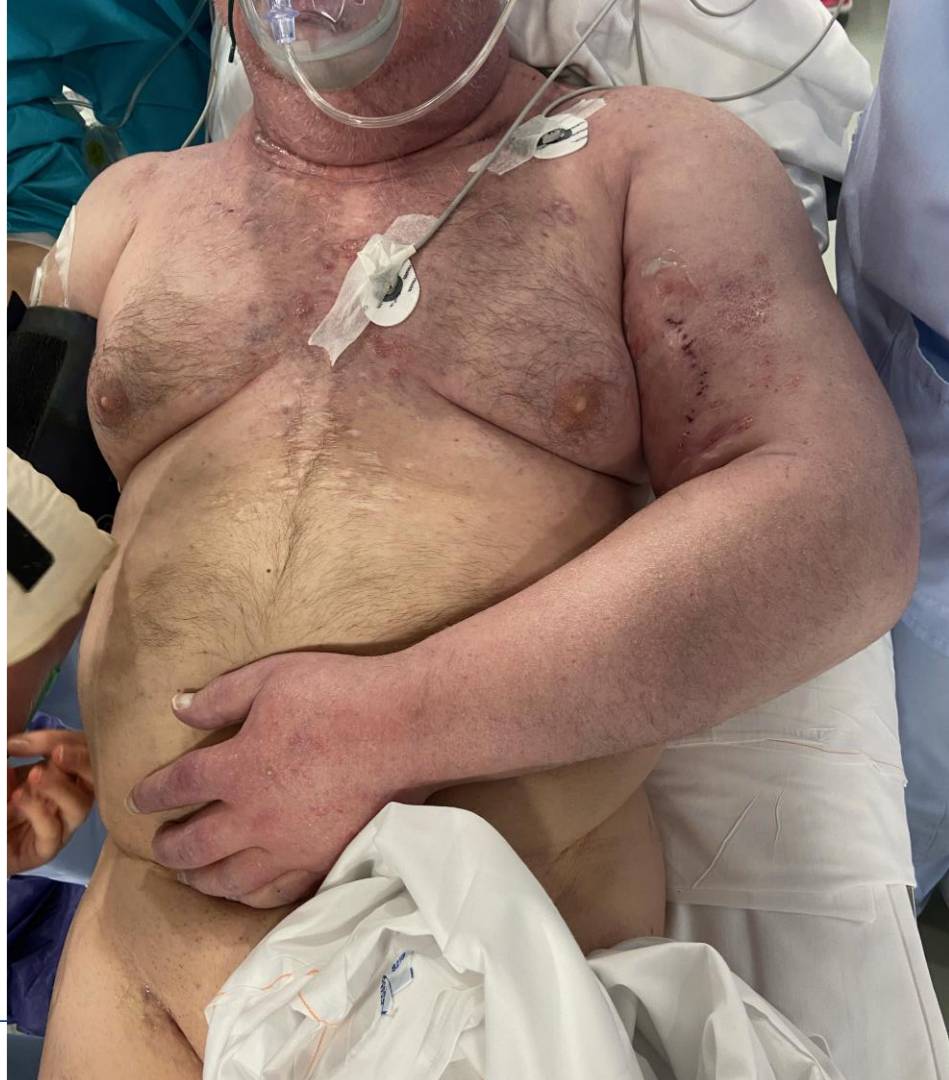

0.62/0.6mm 0,984:1/0.62sp

R
P

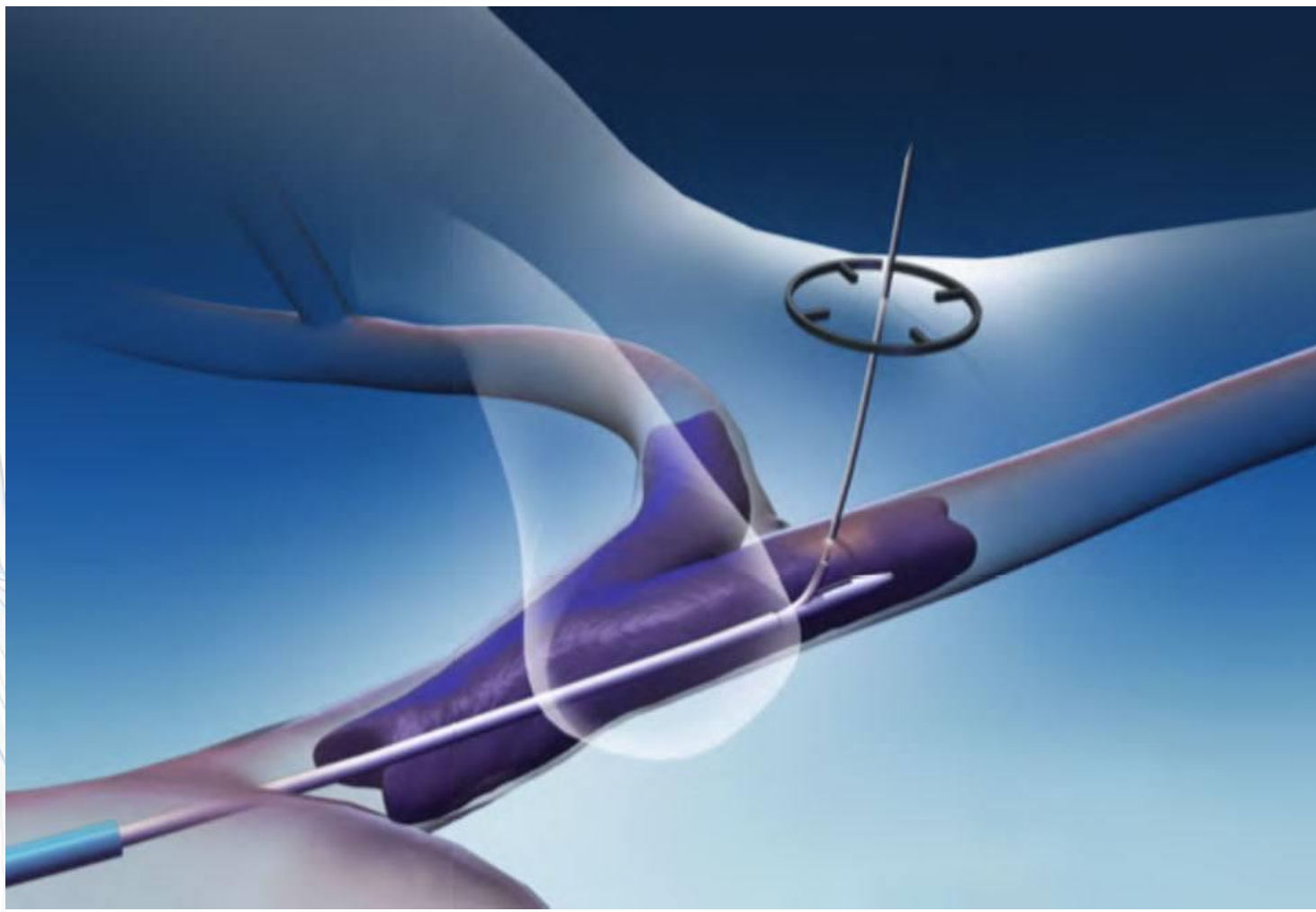
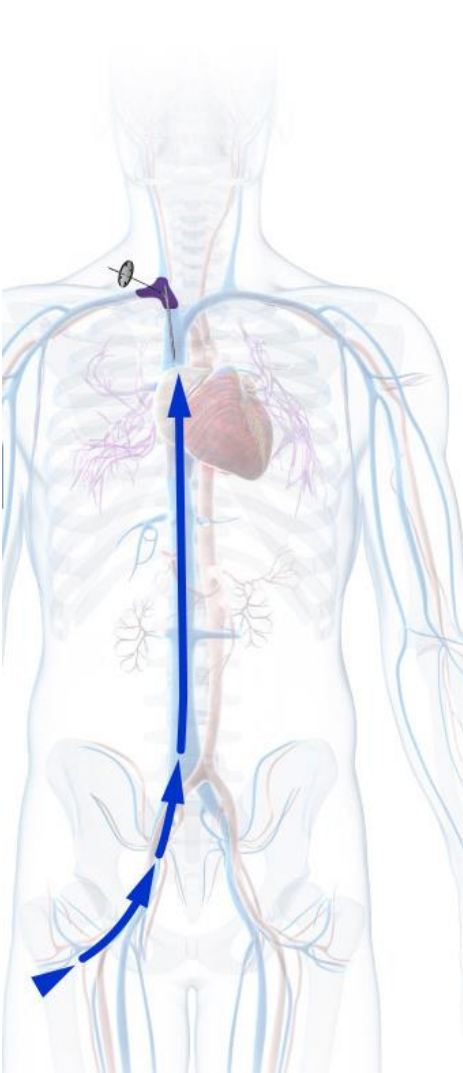
L
A

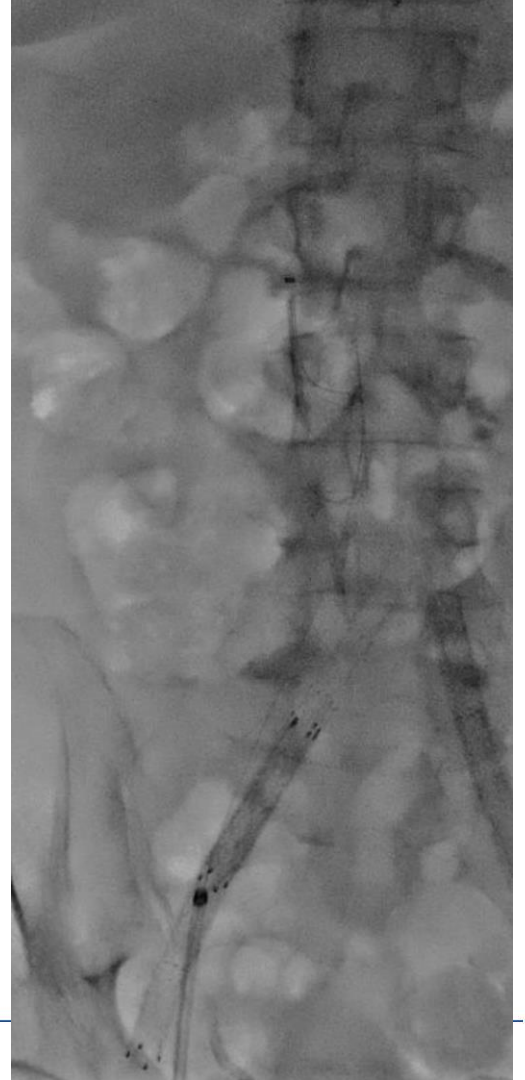
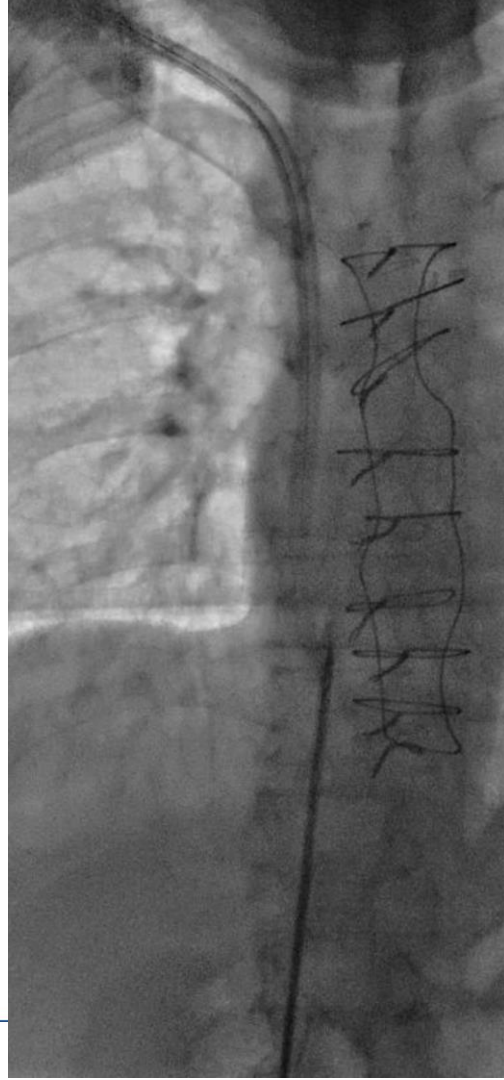
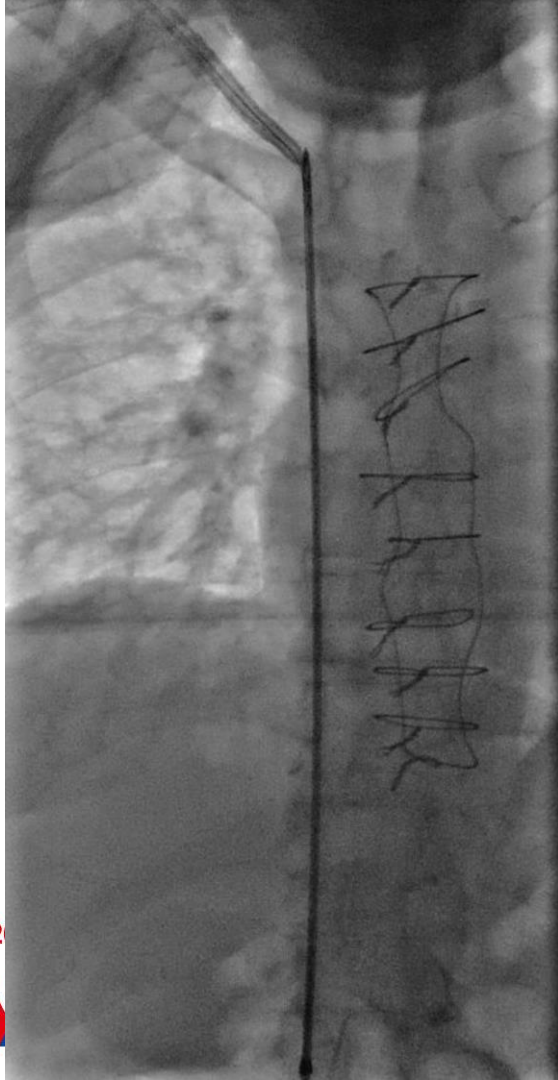


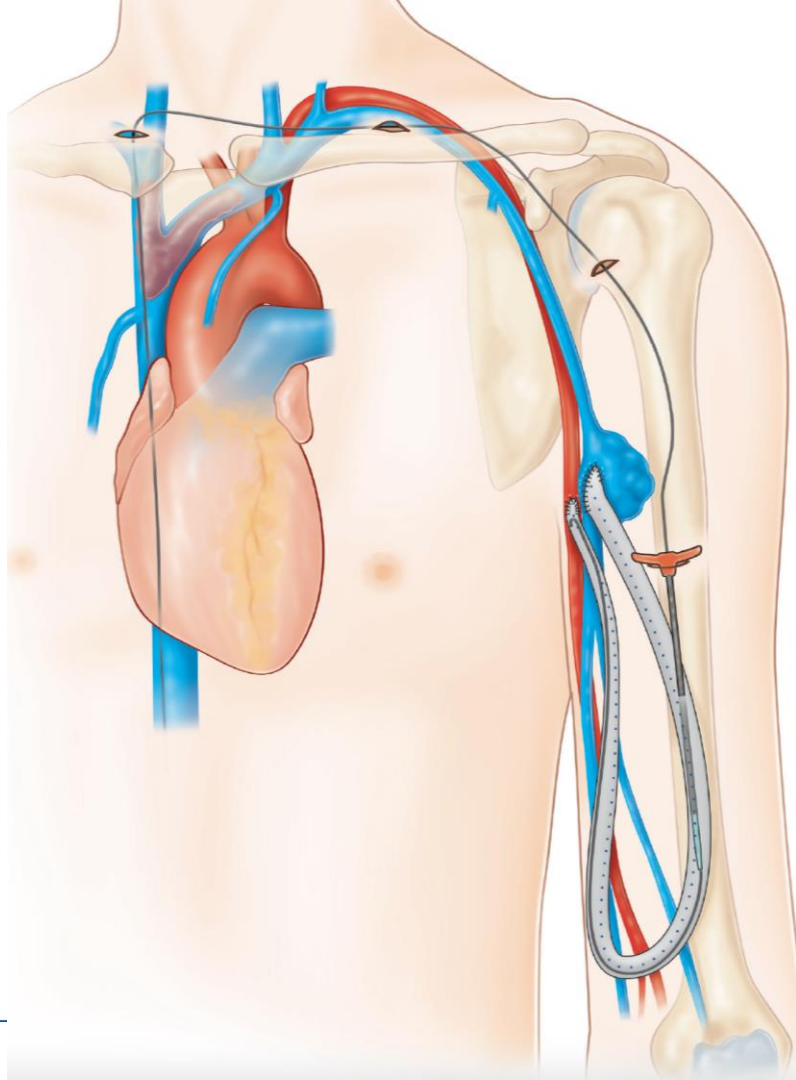


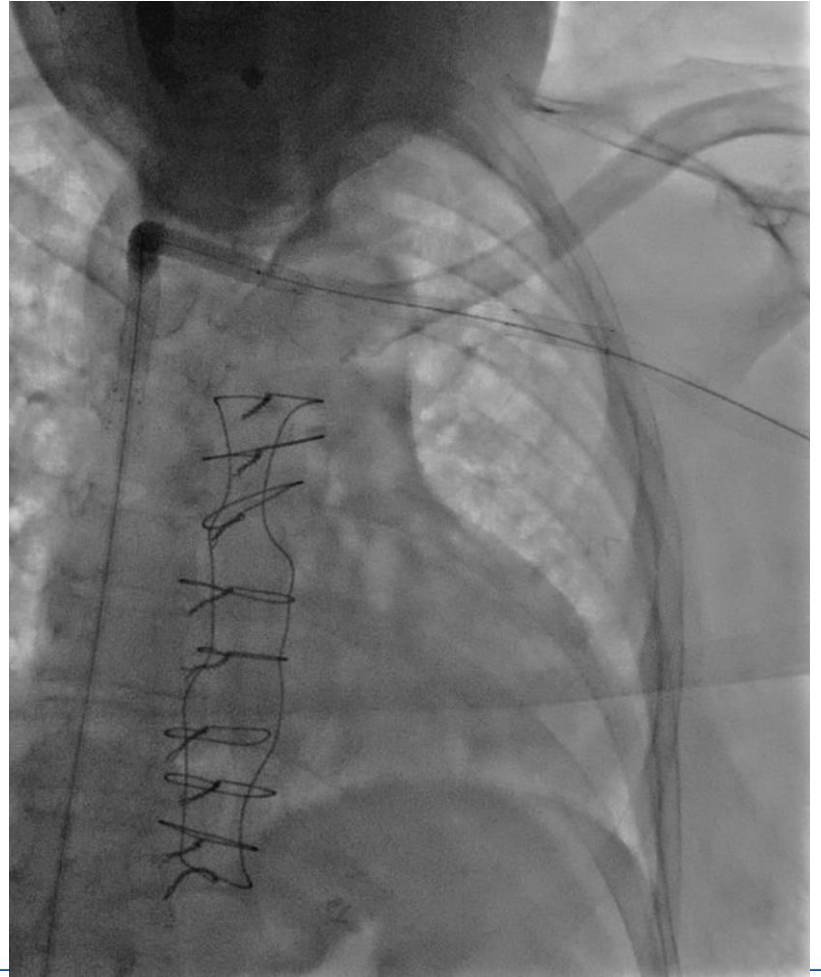
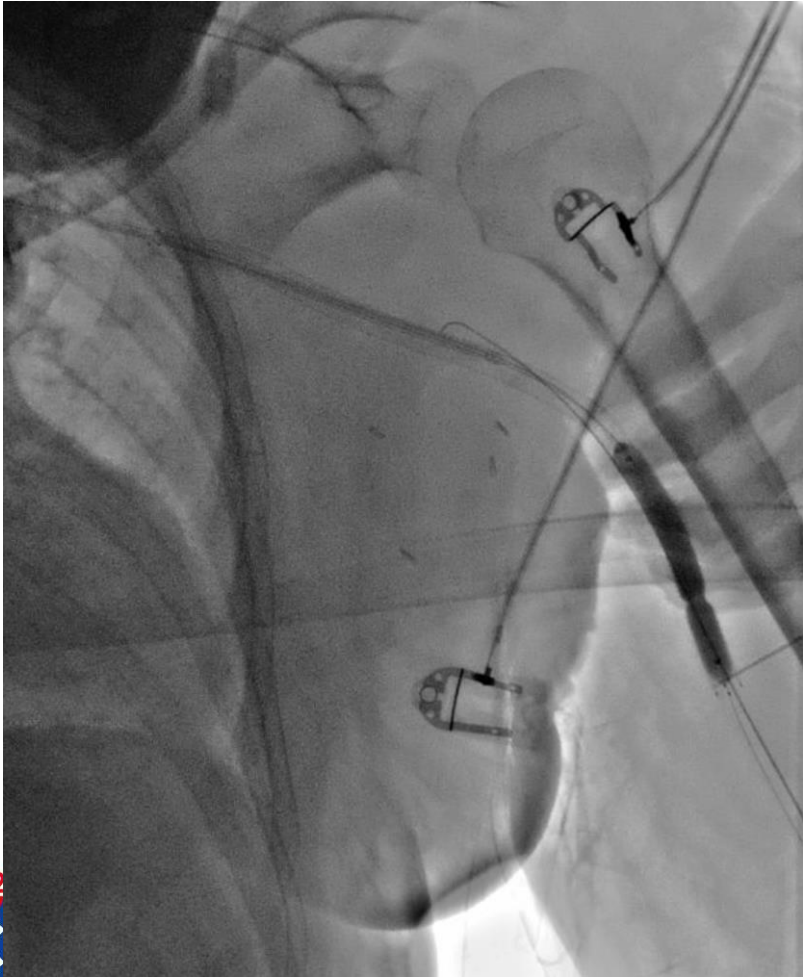
Options

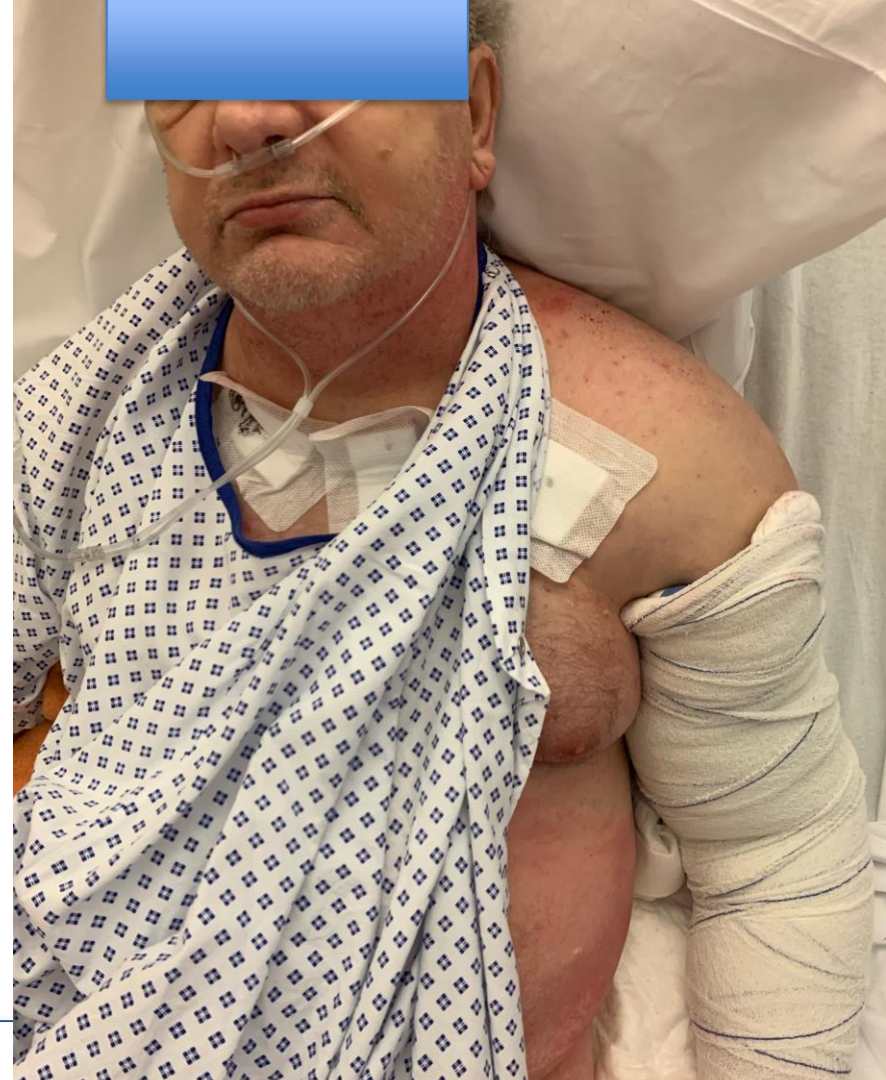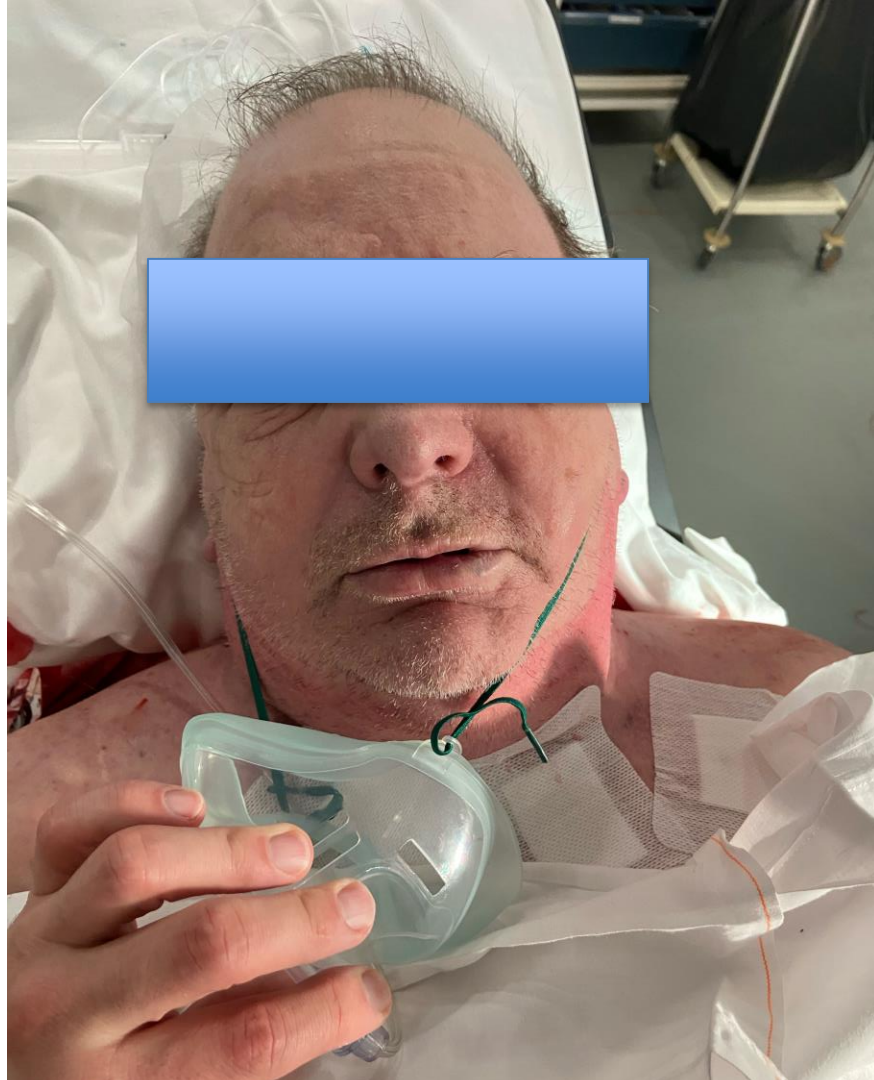- Covered Stent over Pseudo-aneurysm and femoral catheter
- Change your name, number and address and look for cheap plastic surgery face reconstruction
- Think out of the box and do something interesting

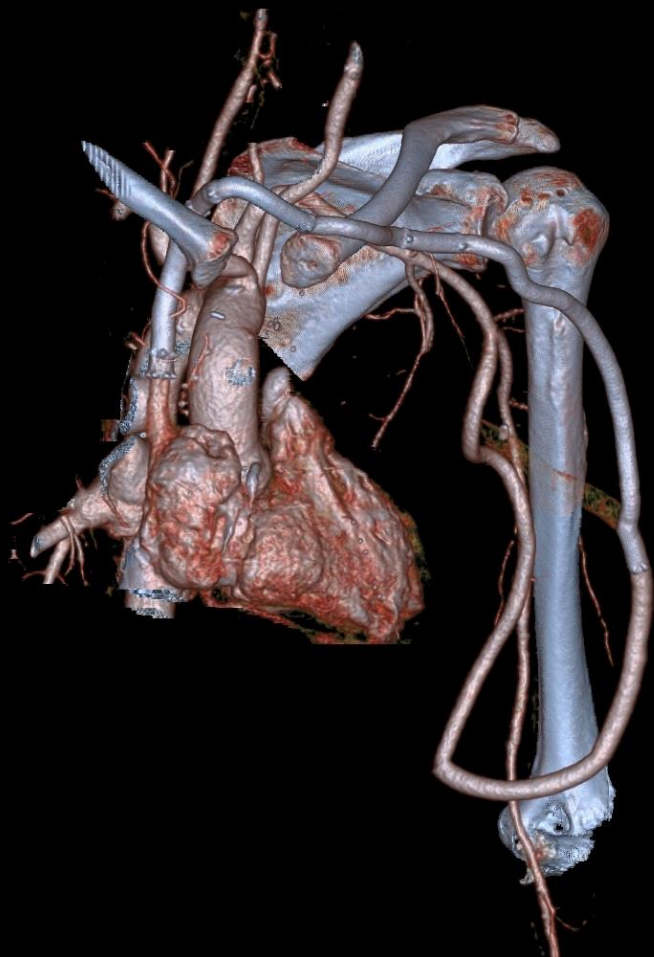








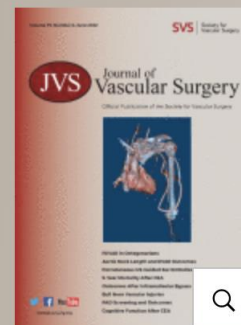




Journal of
Vascular Surgery



Society for
Vascular Surgery



June 2022
Volume 75, Issue

[Current Issue](#) [On](#)