



B O R D E A U X

**PERSPECTIVES 2019**

November  
Friday 29



**Limb arteries endovascular repair : my worst case**

**Mon cas catastrophe périphérique**



Bahaa NASR  
CHU Cavale Blanche – Brest





B O R D E A U X

**PERSPECTIVES 2019**

November  
Friday 29



## **Disclosure**

Speaker name:

**Bahaa NASR**

I have the following potential conflicts of interest to report:

**Consulting: Biotronic, Medtronic**

# Seriously ? R U kidding ?

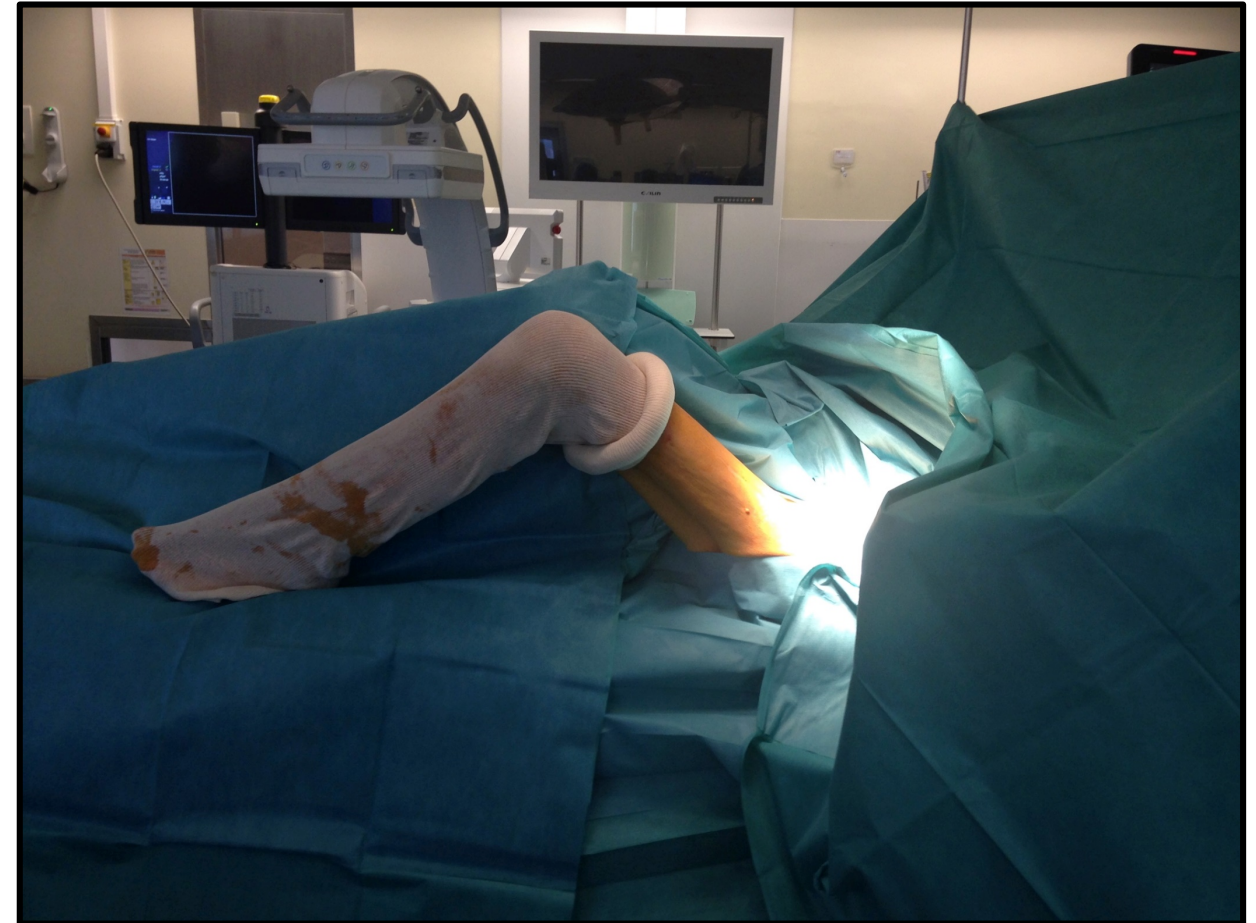
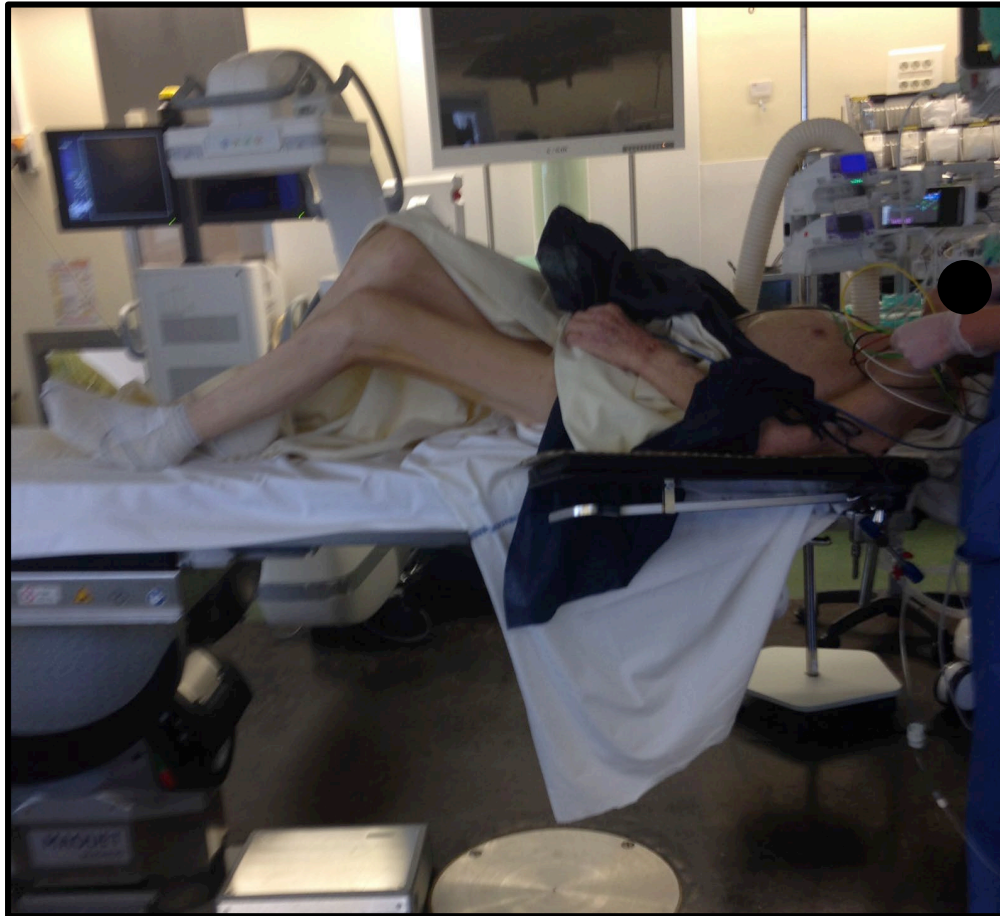## 9.30 – SESSION 2

Moderators: *Nicolas Diard / Daniela Branzan*

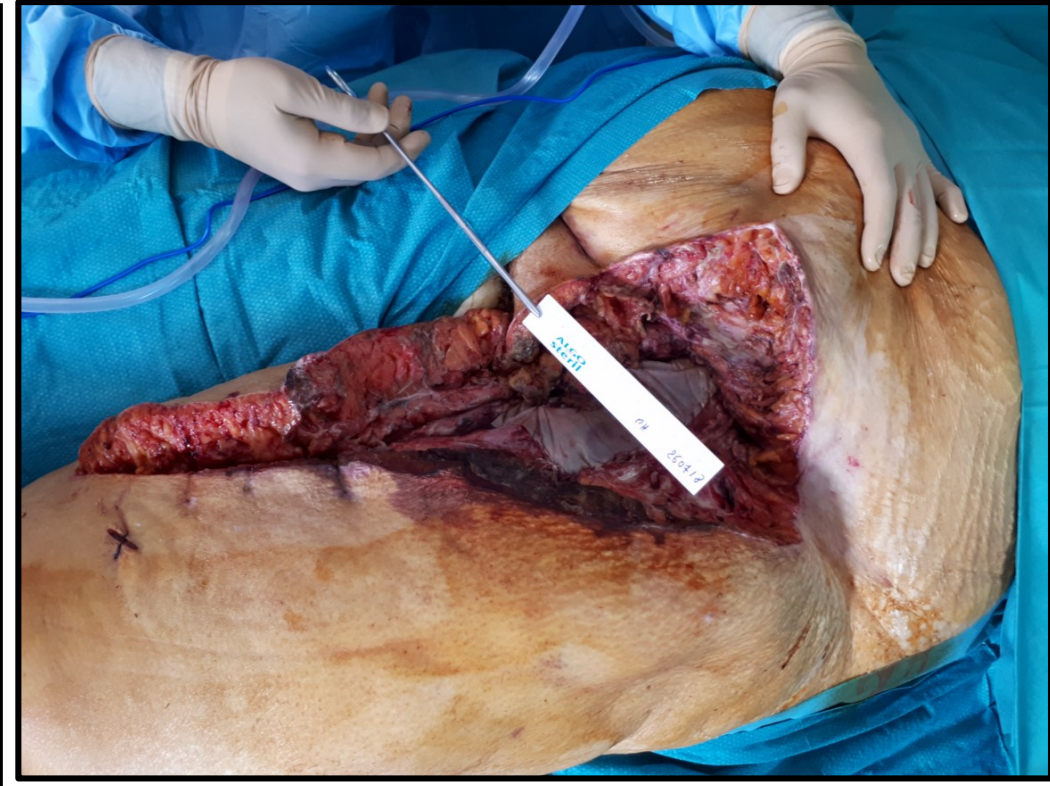
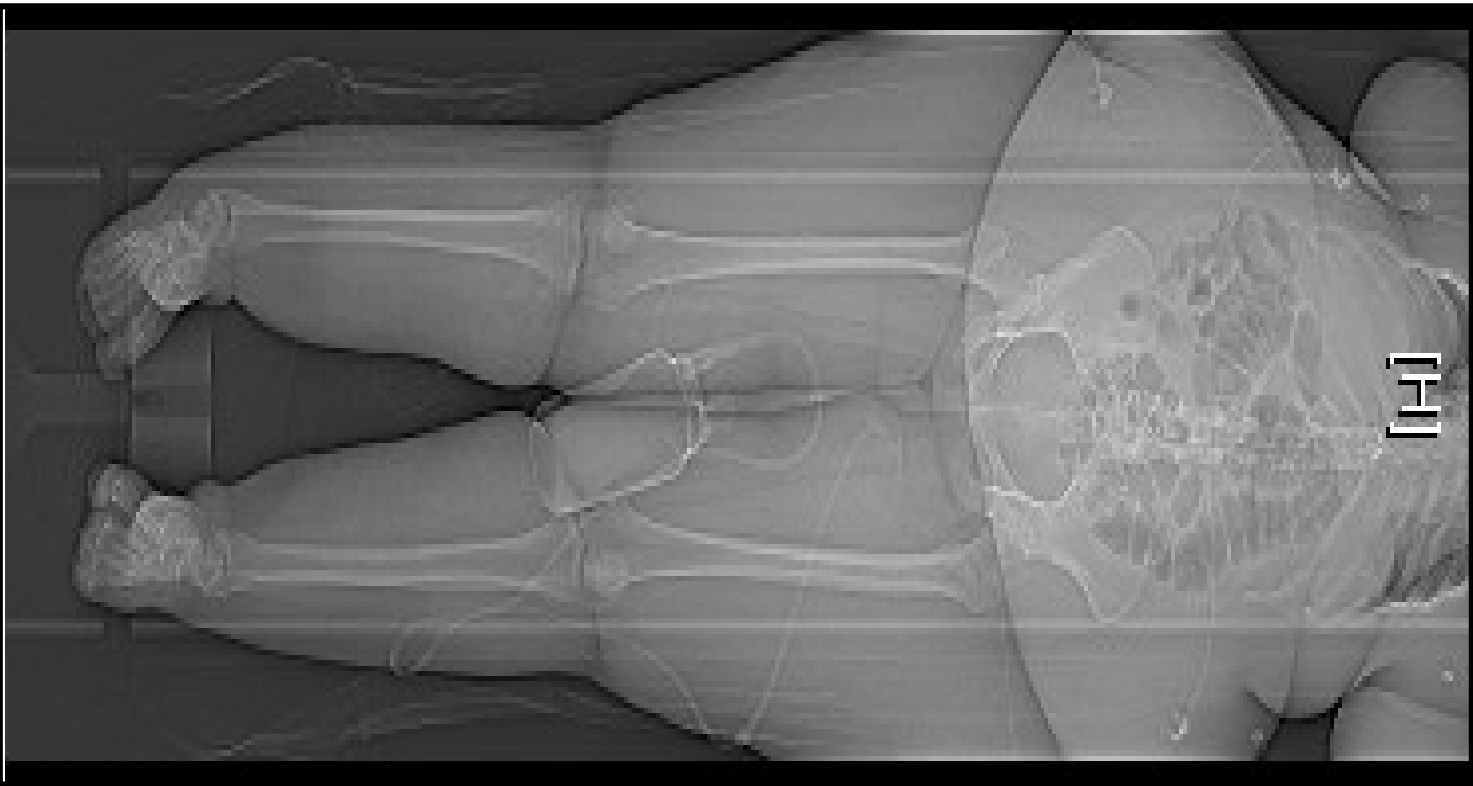
- My nightmarish endovascular case, *Laurent Lagoarde*
- My technique for the future: CTA with image fusion guidance in PAD endovascular repair, *Nicolas Louis*
- Limb arteries endovascular repair : my worst case, *Bahaa Nasr*
- My technique for the future: calcium debulking and his problems, *Benjamin Fialon*
- My worst case, *Michel Bartoli*
- My worst case, *Eugenio Rosset*



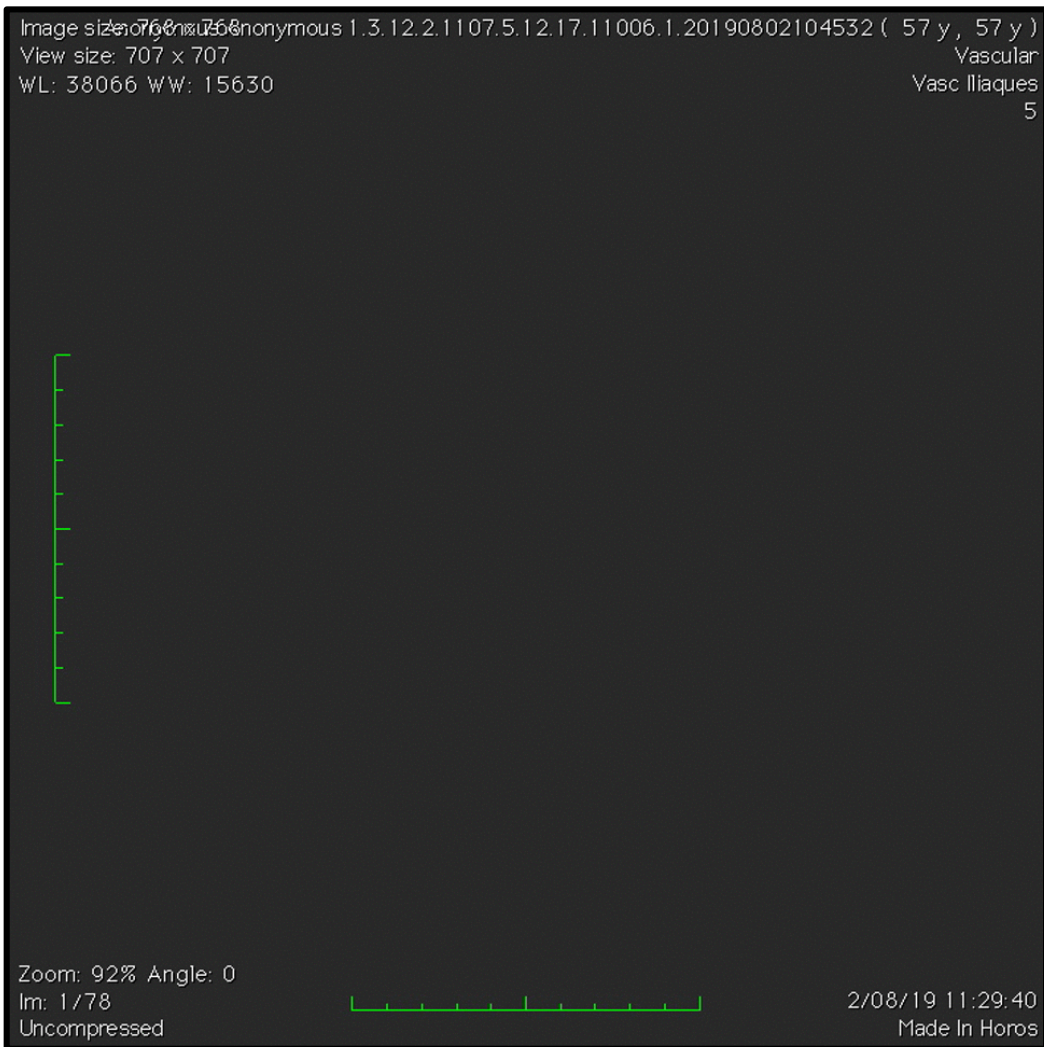
# Worst case: *patient*



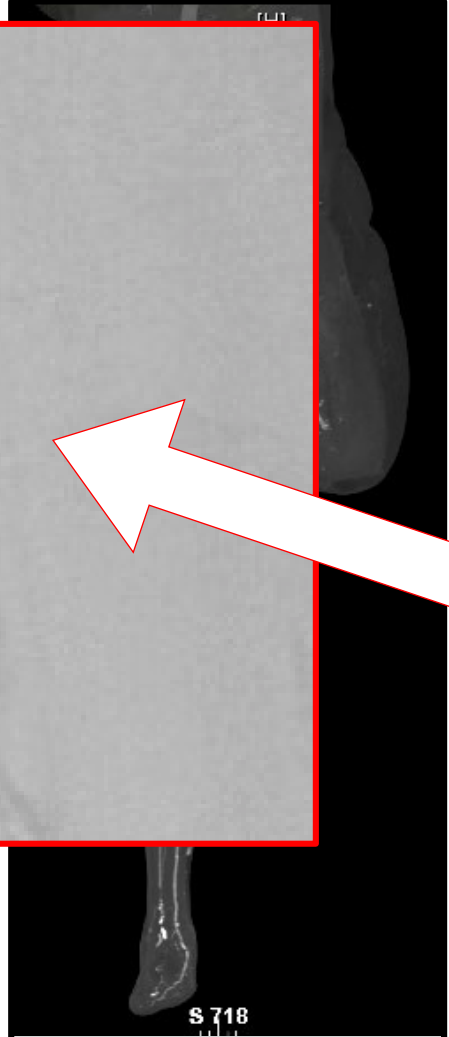
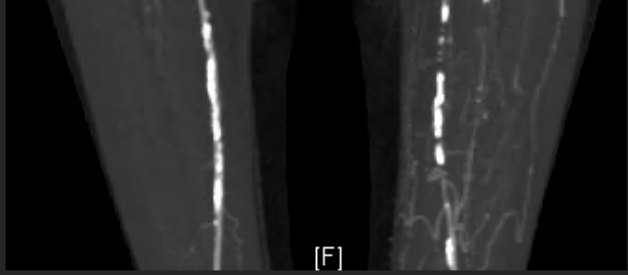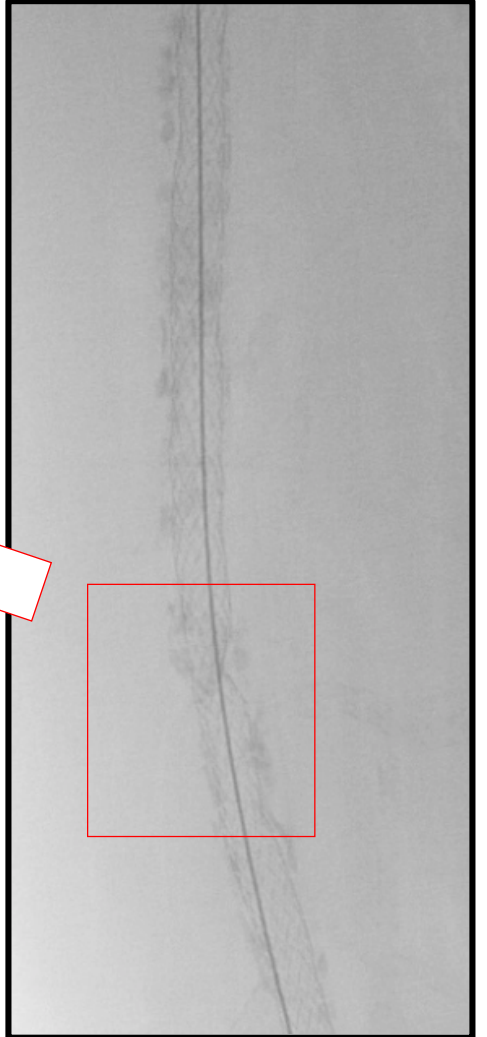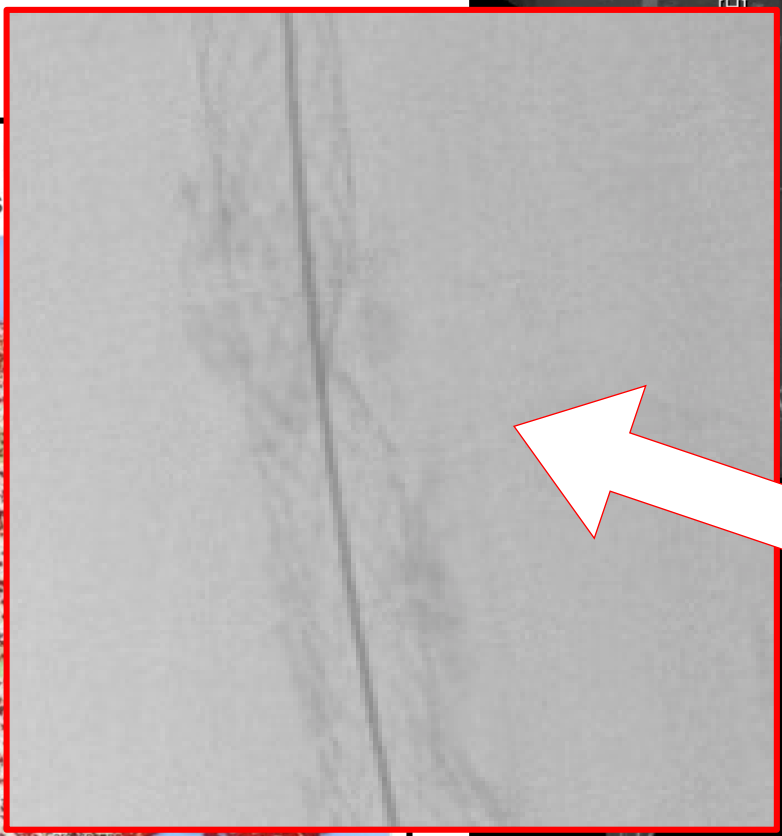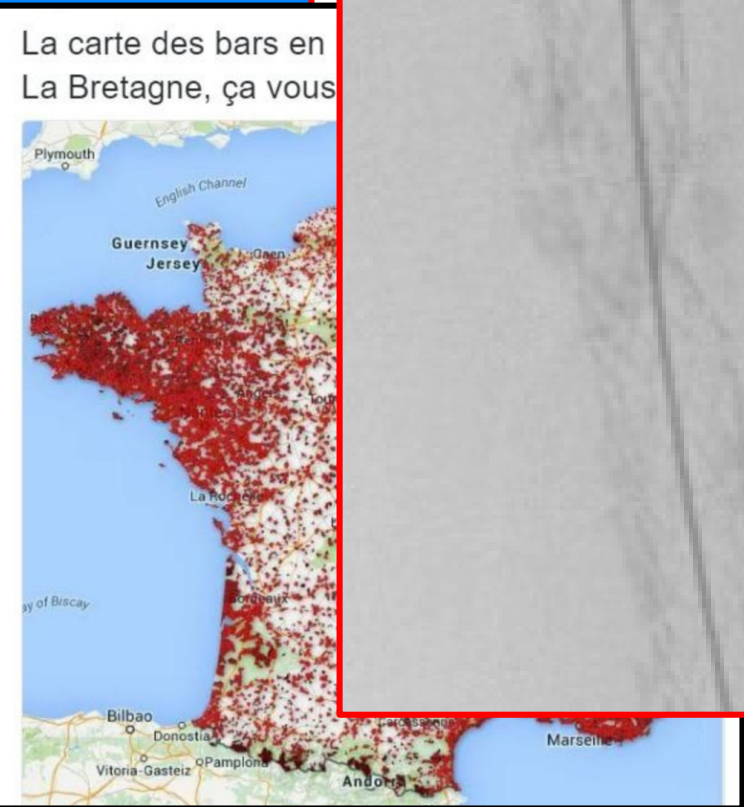
# Worst case: *patient*



# Worst case: *Lesion*



# Worst case: *Lesion*



# My Worst case

Mme B, 79 ans

AOMI: Rutherford VI MIG

ATCD:

AVC ischémique 2008

PPR

HTA

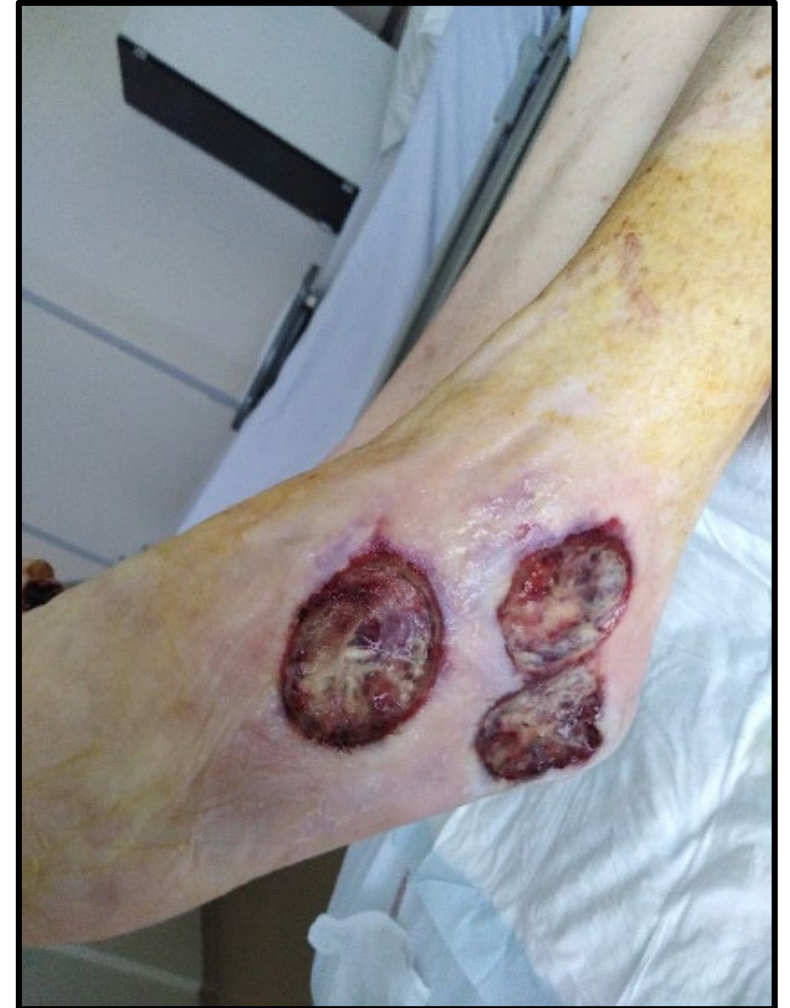Dyslipidémie

Diabète cortico-induit

AOMI: angioplastie stenting AFS droite

Oct 2018: Douleur à l'effort du MSG

Doppler: sténose serrée de l'artère sous  
clavière gauche



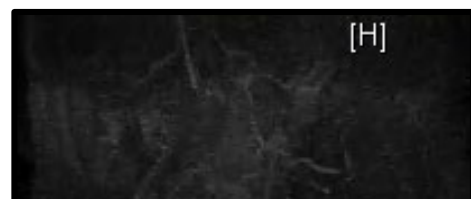

# WIFI Score: W3 / I3 / FI1

	Ischemia – 0				Ischemia – 1				Ischemia – 2				Ischemia – 3			
W-0	VL	VL	VL	VL	VL	L	L	M	L	L	M	M	M	H	H	H
W-1	VL	VL	VL	VL	L	M	M	M	M	H	H	H	H	H	H	H
W-2	VL	VL	VL	VL	M	M	H	H	H	H	H	H	H	H	H	H
W-3	VL	VL	VL	VL	M	M	M	H	H	H	H	H	H	H	H	H
	FI-0	FI-1	FI-2	FI-3	FI-0	FI-1	FI-2	FI-3	FI-0	FI-1	FI-2	FI-3	FI-0	FI-1	FI-2	FI-3

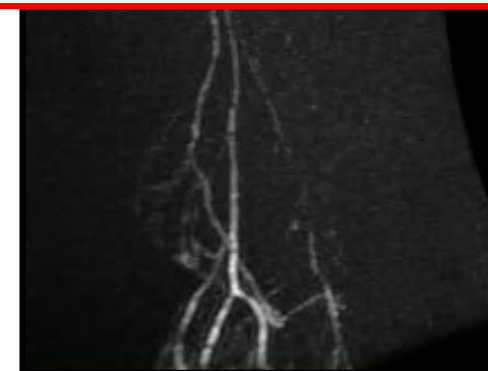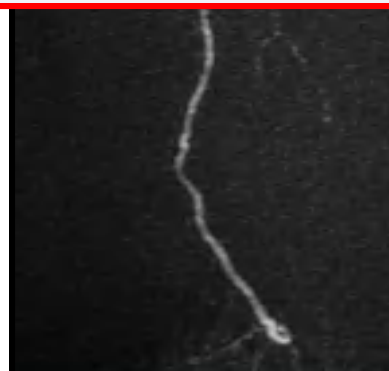

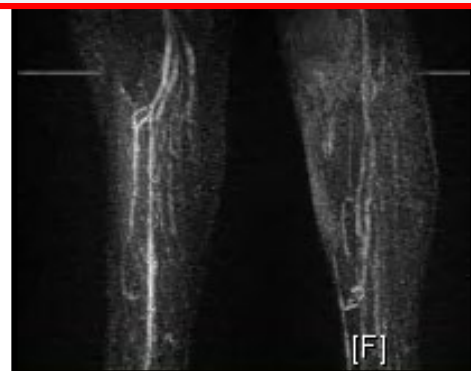
# MRI

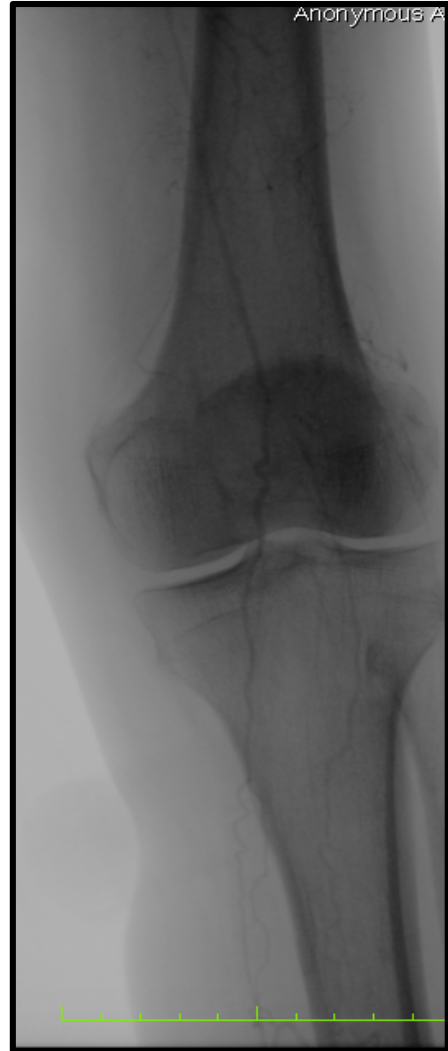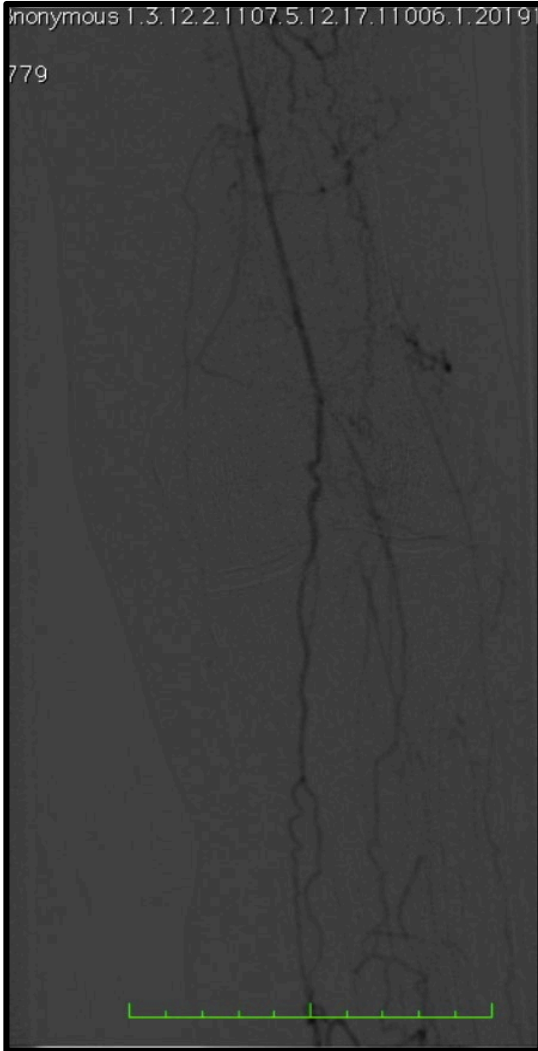


Sténoses irrégulières de la distalité des artères fémorales superficielles et surtout des artères poplitées avec occlusion poplitée gauche. Le caractère long et irrégulier de ces sténoses est habituellement visible dans les artériopathies athéromateuses. Les artères fémorales profondes sont perméables.

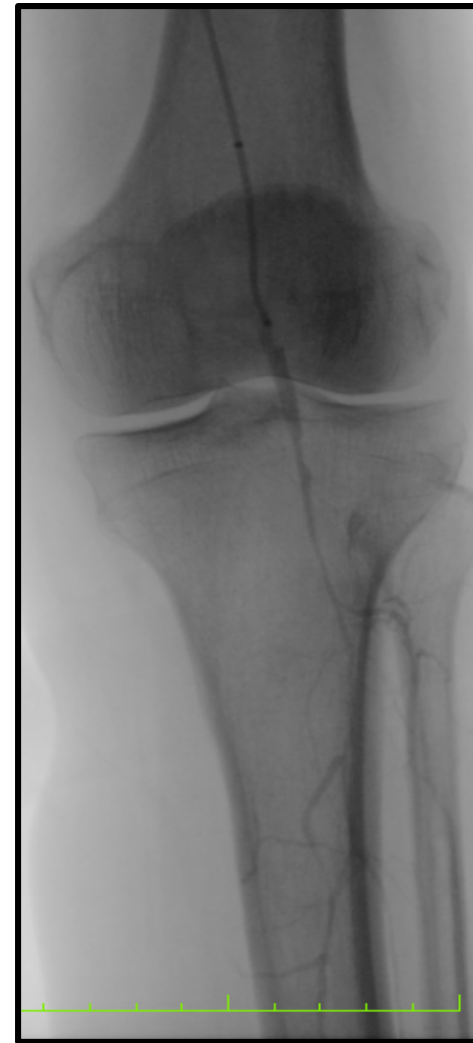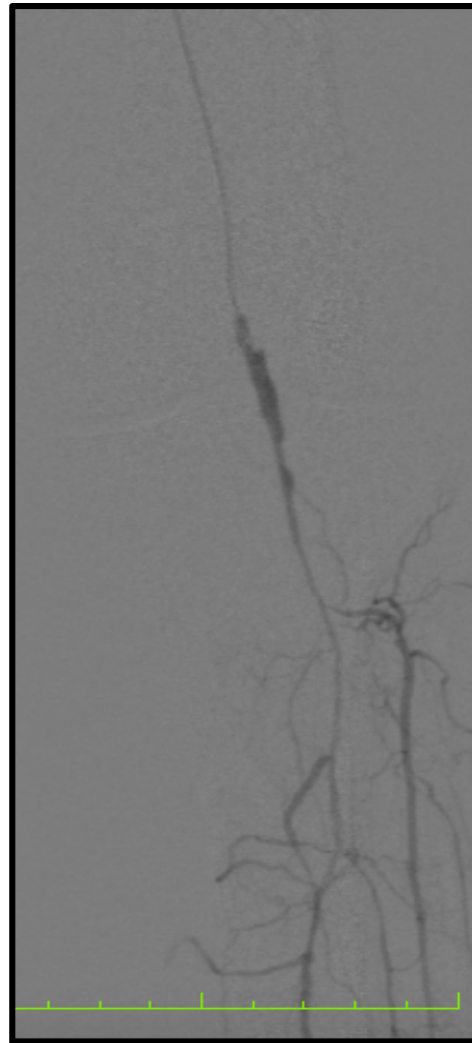

À l'étage jambier gauche, il existe une réinjection de l'artère tibiale postérieure à partir de son tiers supérieur, les autres axes sont occlus. A l'étage jambier droit, infiltration longue et sévère des artères tibiale antérieure et péronière. L'artère tibiale postérieure est bien perméable en aval d'une sténose serrée du tronc tibio-péronier.



# Procédure

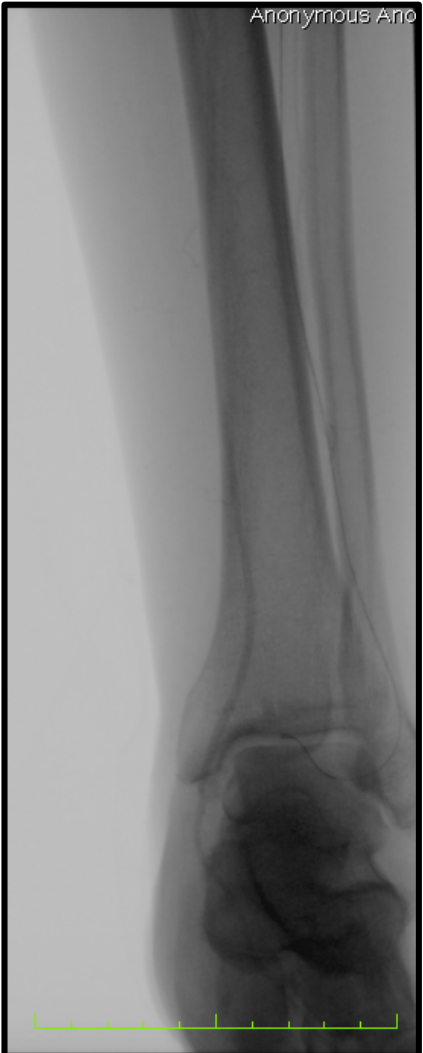
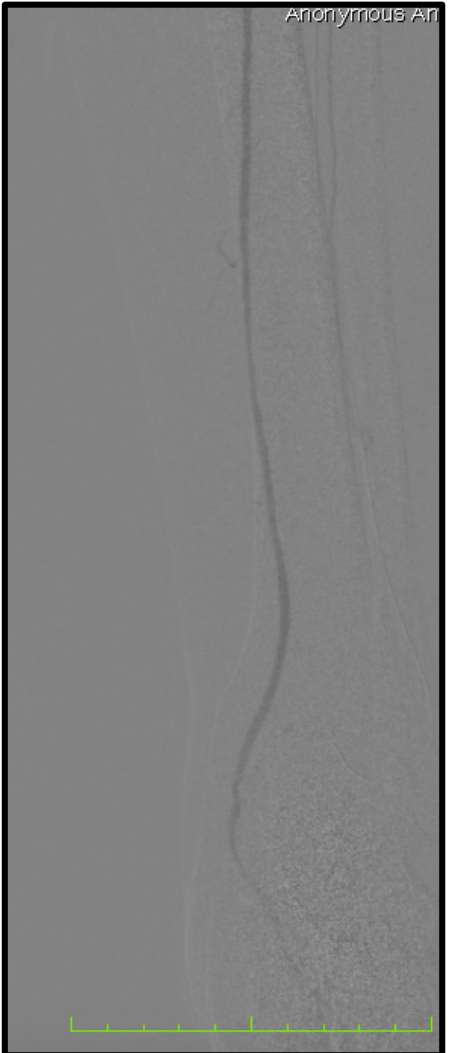

# Procédure



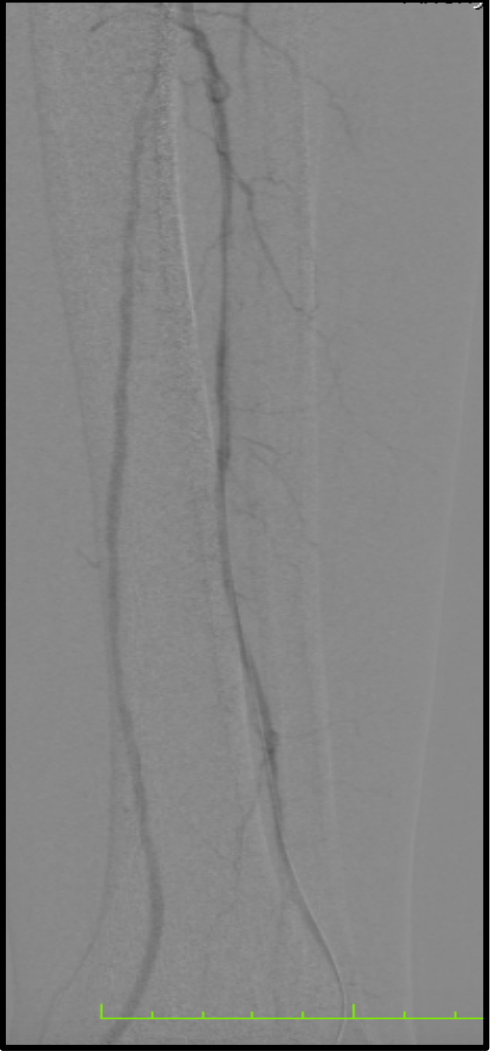
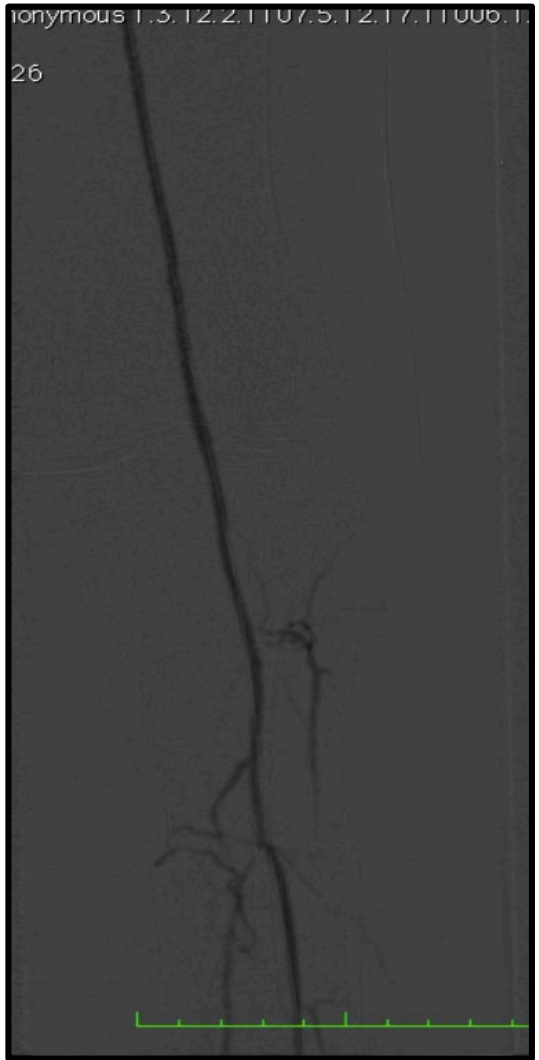
Guide ADVANTAGE®  
Terumo  
Sonde Navicross®

# Procédure

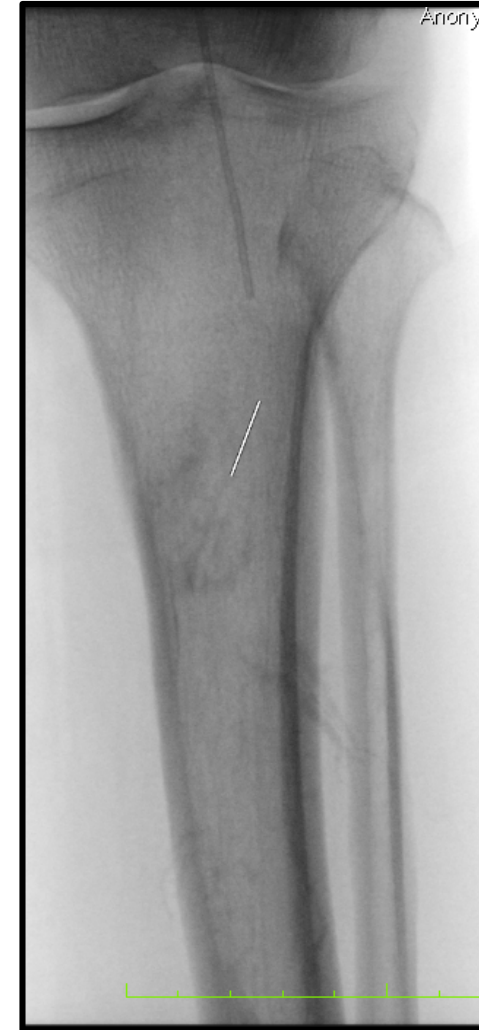
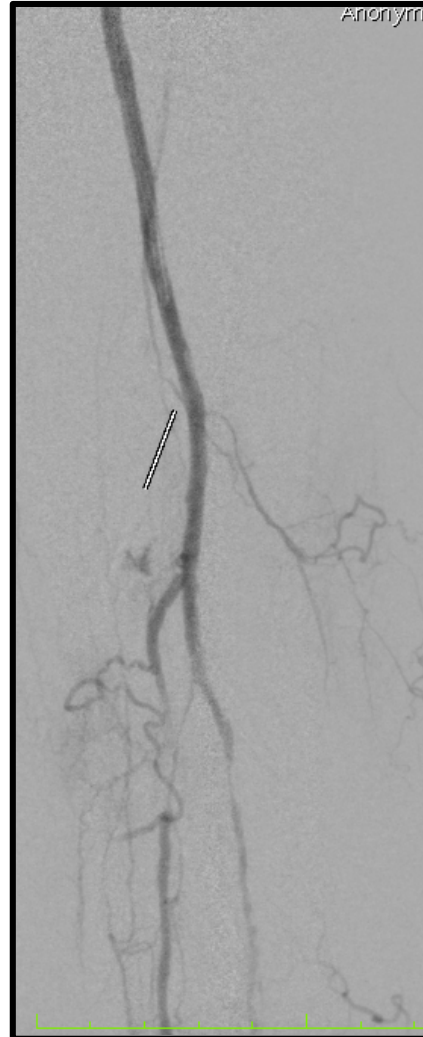



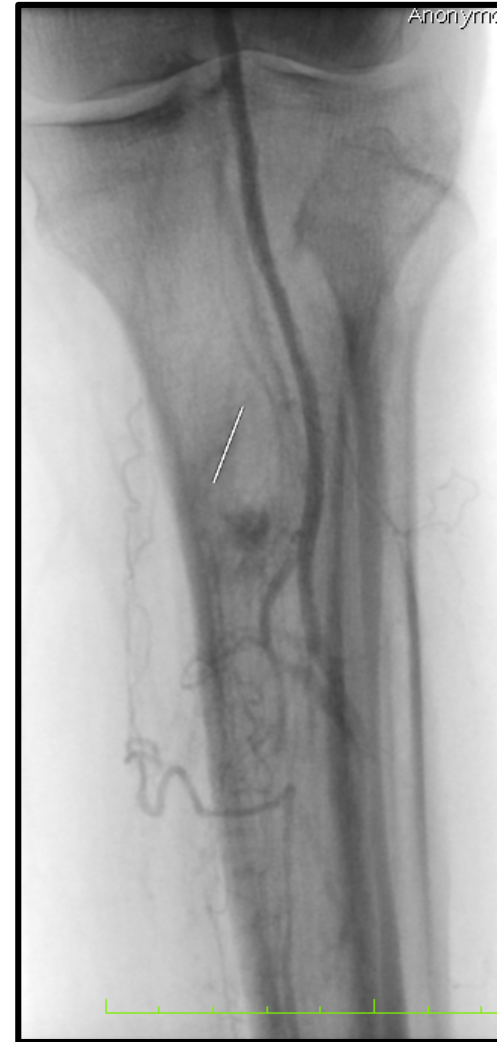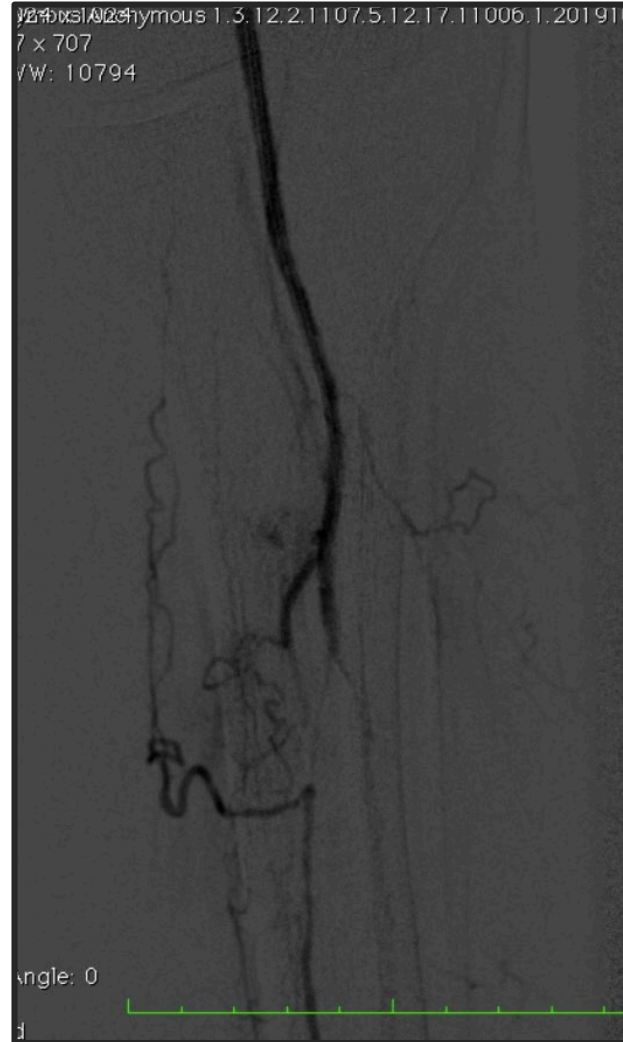

# Procédure



# Procédure



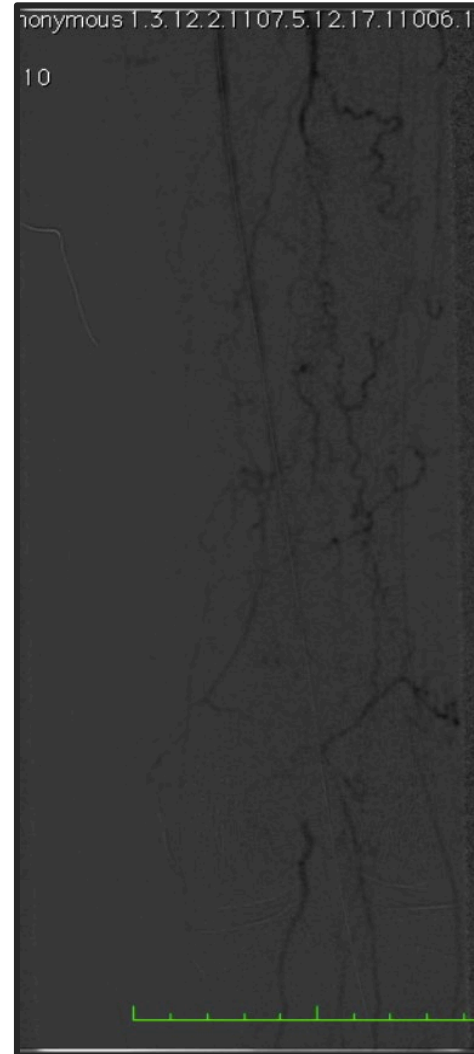

# Procédure



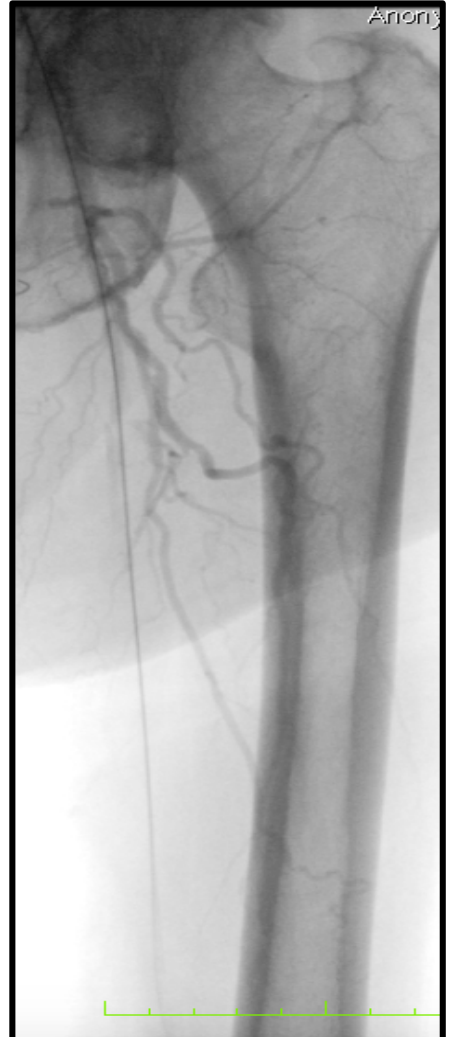
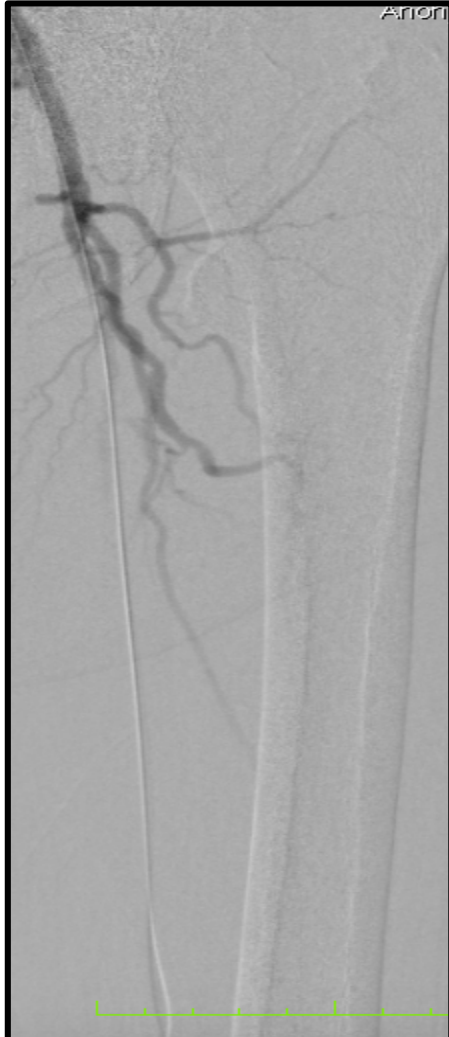




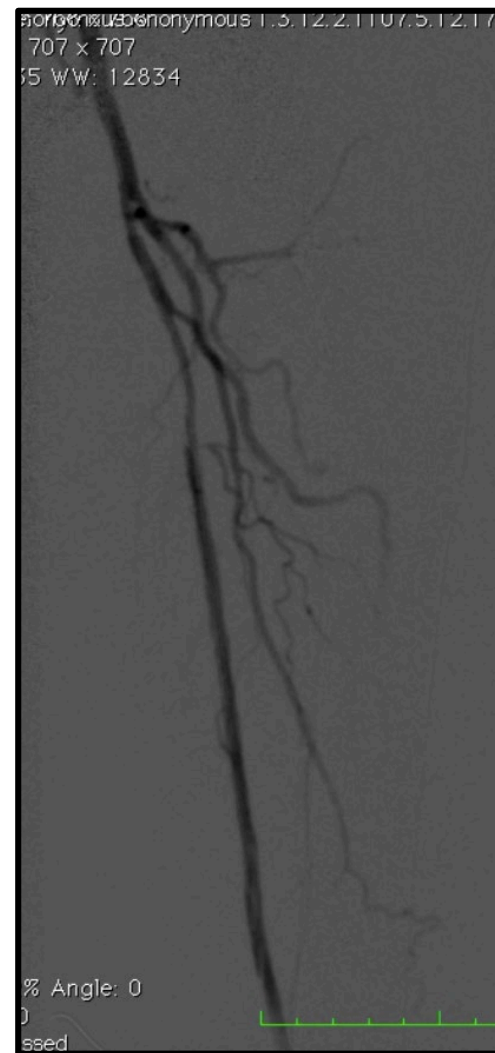
# Procédure



# Procédure



# Procédure







# Procédure

anonymous 1.3.12.2.1107.5.12.17.1100

0

12.2.1107.5.12.17.11006.1.20190

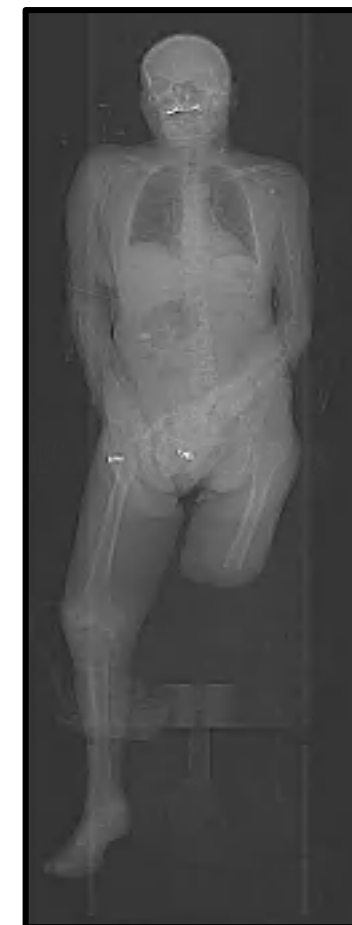



# Suivi

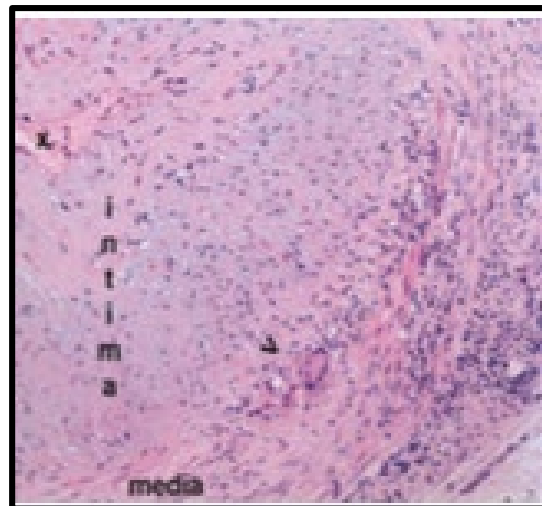
- J1: aggravation des douleurs et de l'ischémie
- Doppler: occlusion du stent et des 3 axes jambiers
- Amputation trans-tibiale gauche.  
**Biopsie artère péronière**

**Doppler:** sténose serrée de l'artère sous clavière gauche, **halo hypoéchogène (artérite inflammatoire gros Vx, Horton?)**

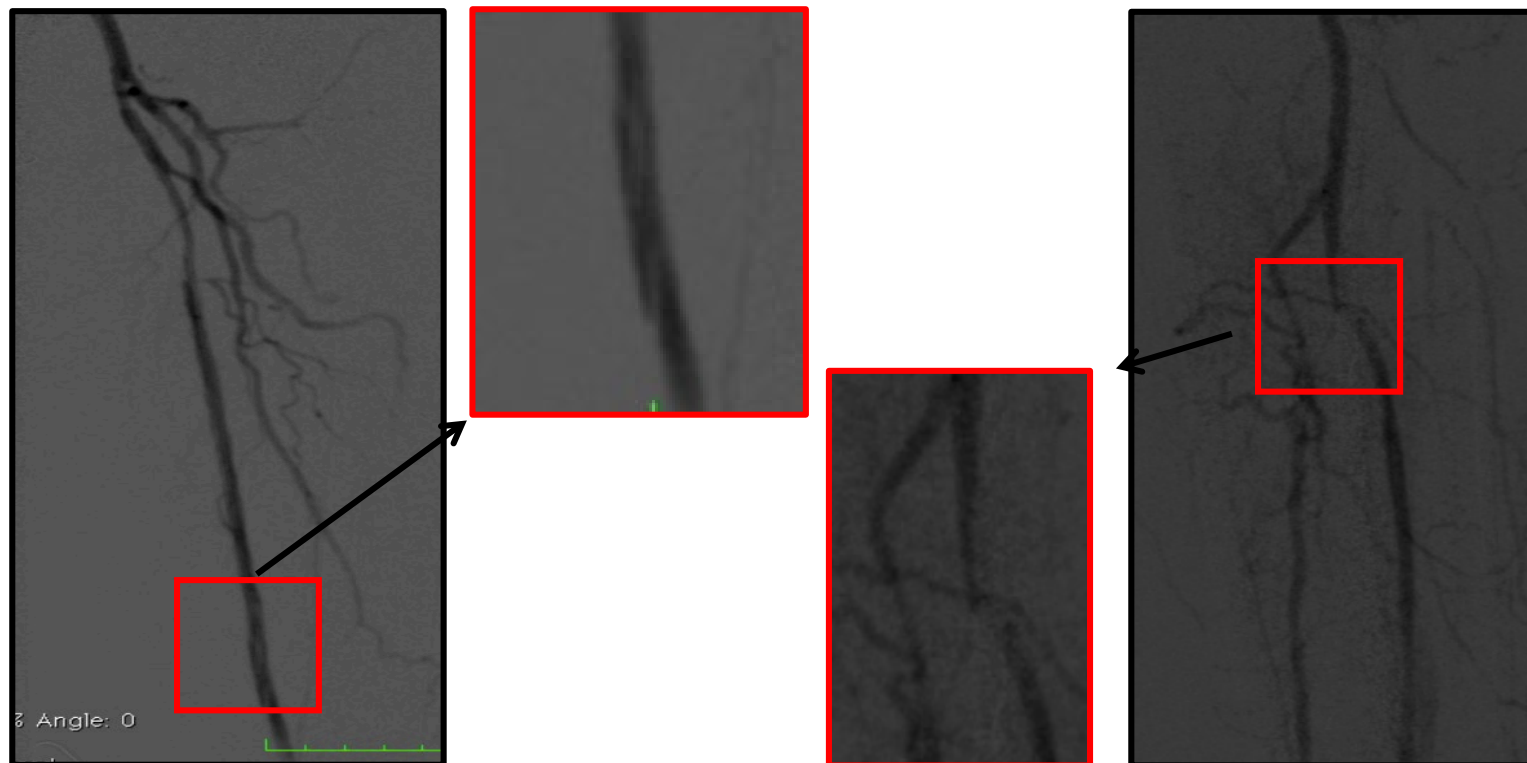


# Hypothèses

Maladie inflammatoire  
Horton



Dissection AFS / poplité



Lit d'aval

**I am ready !!!**

